

## CASE REPORT

# Complete Fracture-dislocation of the Lumbar Spine Without Neurologic Deficit: A Case Report and Review of Literature

Yehia ElBromboly, MD \*, Amr A. Mohamed, MD

Orthopedic Surgery Department, Faculty of Medicine, Zagazig University, Egypt

### Abstract

**Background data:** Traumatic spondyloptosis is a rare spinal injury, especially in the absence of a neurologic deficit. Urgent and safe management of this injury poses a significant burden on the spine surgeon.

**Purpose:** To report a case of complete fracture-dislocation at L4-5 without neurologic deficit.

**Study design:** A case report.

**Patients and methods:** A 34-year-old male who works as a manual worker presented to our emergency department after a heavy object fell on his back. He was diagnosed with traumatic L4-L5 spondyloptosis without a neurologic deficit. The body of L4 with the spinal column above was totally displaced in front of the body of L5. The posterior elements of L3 and L4 were fractured, causing spontaneous decompression of the neural tissue. He underwent urgent surgery the next day in the form of posterior instrumentation, reduction, and interbody fusion.

**Results:** The patient's neurologic function remained unchanged after surgery and throughout the postoperative period of 9 months.

**Conclusion:** Complete fracture-dislocation of the lumbar spine is a rare injury, especially without a neurologic deficit. This could be explained by the spontaneous neurologic decompression achieved through fractures in the posterior elements. Urgent surgical intervention is of paramount importance in preserving neurologic function and achieving good clinical results.

**Keywords:** Complete fracture-dislocation, Spontaneous neurologic decompression, Traumatic spondyloptosis

## Introduction

**T**raumatic spondyloptosis is defined as greater than 100% subluxation of a vertebral body regarding the vertebral body beneath it in the sagittal plane secondary to a traumatic event. It is also described in the literature as grade 5 spondylolisthesis. It is a severe form of translational spinal injury where one vertebra is lodged in front of the subsequent one. This is a rare injury pattern that is usually accompanied by a devastating neurologic

insult, understandingly due to the enormous amount of spinal translation [1]. This report describes our experience with a case of traumatic L4-L5 spondyloptosis without a neurologic deficit.

## Case report

A 34-year-old man presented to our emergency department after an accident at a construction site where a heavy object fell on the patient's back. On initial examination, the patient was alert and oriented. His Glasgow coma scale was 15/15, with no problems

Received 2 August 2022; revised 29 August 2023; accepted 1 September 2022.  
Available online 1 October 2022

\* Corresponding author. Orthopedic Surgery Department, Faculty of Medicine, Zagazig University, Zagazig, Egypt.  
E-mail address: [yehiaelbromboly@gmail.com](mailto:yehiaelbromboly@gmail.com) (Y. ElBromboly).

Online ISSN: 2314 - 8969; Print ISSN: 2314 - 8950; [esj.researchcommons.org](http://esj.researchcommons.org)



<https://doi.org/10.57055/2314-8969.1275>

2314-8969/© 2022 Egyptian Spine Association. This is an open access article under the CC-BY-NC-SA license (<http://creativecommons.org/licenses/by-nc-sa/4.0/>).

in the airway, breathing, and circulation. He reported severe pain in his lower back and left arm. Clinical examination revealed abrasions and bruises at both sites. Neurological examination showed normal motor power throughout the lower limbs bilaterally apart from a minor weakness of right L5 (extensor hallucis longus) grade 4 with some paresthesia on the right side on the dermatomal distribution of L4 and L5. Also, he had normal sphincteric control.

Radiological evaluation initially included plain radiographs and a computed tomography (CT) scan. Plain radiographs revealed complete fracture-dislocation at L4-L5 and a distal humerus fracture. The CT scan demonstrated the spondyloptosis clearly, with fractures of the posterior arches of L3 and L4 separating the posterior elements from the vertebral bodies and fractures of the transverse process of L1, L2, L3, and L4. Axial cuts showed the double sun appearance characteristic of spondyloptosis and the wide separation of the posterior vertebral arch at the level of L4. Magnetic resonance imaging (MRI) was done the following morning, about 12 h after the patient's admission. It showed complete dural sac obliteration, disruption of the L4/L5 disc space, and, more strikingly, an increase in the amount of L4 sagging in relation to L5. The aim of doing the MRI was to evaluate further the neural structures and the extent of soft tissue injury (Fig. 1).

Surprisingly, the MRI images done the next morning demonstrated that the lower end plate of L4 nearly reached the level of the lower end plate of L5, denoting increased vertebral displacement compared to the sagittal reconstruction images of the CT that showed the lower end plate of L4 directly in front of an upper-end plate of L5 at time of admission.

We decided to proceed with surgical stabilization of the fracture, taking into consideration the obvious instability of the fracture while using the Thoracolumbar Injury Classification and Severity (TLICS) Score as a decision-making tool. The patient's TLICS score was 6 (3 for the translational injury pattern and 3 for the injured posterior ligamentous complex). The patient was taken to the operative theater around 16 h after admission. Repeat neurological examination revealed no change in previous findings immediately postoperatively.

After general anesthesia, the patient was carefully logrolled into a prone position. We were able to achieve a partial reduction in the displacement by maximizing hip flexion while prone on the operating table (Fig. 2). A classic midline posterior approach was utilized, denoting extensive soft tissue injury. The traumatic hematoma was evacuated, then we proceeded with subperiosteal stripping of paraspinal muscles on one side. This was followed by pedicle screw instrumentation in L2, L3, L5, and S1 with the placement of a temporary rod. After that, we completed the exposure on the other side, instrumented the same levels, and put another temporary rod.

The posterior elements of L3 and L4 were already disrupted from the trauma, so we completed a wide decompression of L3/L4 and L4/L5. Then, a ventral dural tear was noted extending from L3 down to L5 that was deemed unrepairable. At that point in the surgery, we started doing gradually controlled distractions on both sides to gradually reduce L4. Afterward, the left temporary rod was removed then we inserted a reduction (long tulip) pedicle screw in L4 to improve the position of L4. Subsequently, the final contoured rod was placed on the left side,

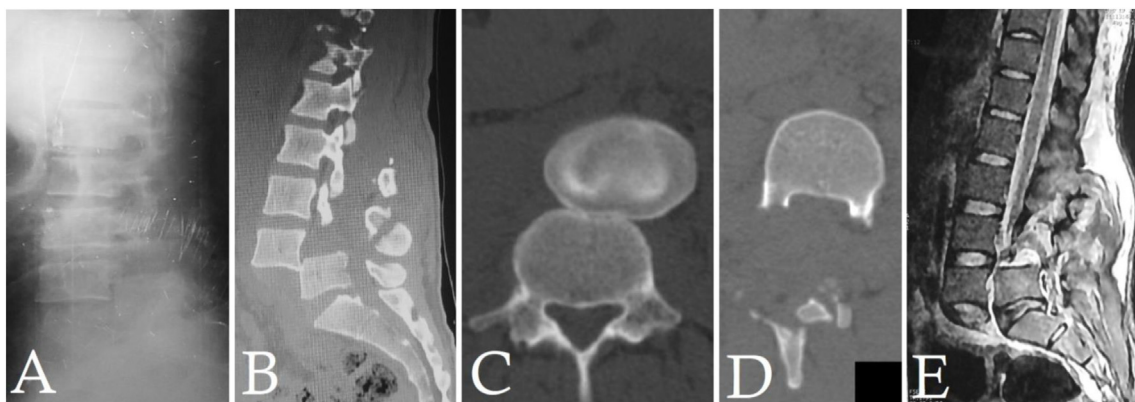


Fig. 1. (A) Preoperative lateral view X-ray showing complete fracture-dislocation of L4-5, (B) Preoperative sagittal CT reformat showing complete displacement of L4 in front of L5, (C) Preoperative axial CT image showing the characteristic 'double sun' appearance, (D) Preoperative axial CT image showing bilateral pedicular fractures of L4 separating the posterior arch of L4 from the vertebral body creating space for the thecal sac, (E) Preoperative MRI sagittal image showing the increased sagging of L4 in front of L5 and the severe transition of the thecal sac.

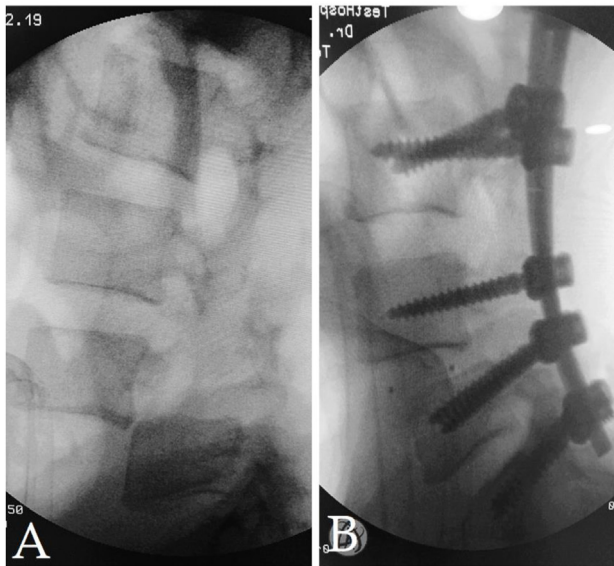


Fig. 2. (A) Intraoperative fluoroscopy image showing the partial reduction of L4 after prone positioning and maximizing hip flexion, (B) Intraoperative fluoroscopy image showing the final L4 position after interbody cage placement.

followed by the replacement of the right temporary rod with the final one (Fig. 2).

Finally, the L4-L5 disc was removed, both end plates were meticulously prepared and the posterior interbody PEEK cage was inserted to induce interbody fusion at the L4/L5 level (Fig. 2). A nonsuction drain was inserted due to the irreparable ventral dural tear, followed by standard closure of the thoracolumbar fascia, subcutaneous tissues, and skin.

Postoperatively, the patient was admitted to the intensive care unit (ICU) for six days. On postoperative day 1, pelvic-abdominal follow-up

ultrasound showed minimal intraperitoneal free fluid with lax abdomen managed conservatively and resolved completely over the next couple of days. On the second postoperative day, the patient developed right-sided hemothorax that was managed by the insertion of a chest tube that was removed on postoperative day 5 after draining around 900 ml of blood.

The nonsuction wound drain was removed on the 9th postoperative day after draining around 1000 ml of fluid (blood and CSF). The patient was kept in reversed Trendelberg position for three days. The patient retained the same neurologic status as compared with the preoperative.

At the first follow-up visit, six weeks after surgery, the patient was ambulating freely. The parathesis on the L4/5 dermatomal distribution resolved. However, the slight weakness of the right L5 remained unchanged. His X-rays showed mild loss of reduction but generally good alignment (Fig. 3). At the final follow-up visit, 9 months postoperatively, the patient was back to his regular daily activities with the same neurologic function as previously. His X-rays showed unchanged alignment (Fig. 3).

## Discussion

Thoracolumbar fracture-dislocations (TLFD) are caused by high-velocity trauma. There is typically complete disruption of the stabilizing ligaments, facet joint capsules, and paraspinal musculature resulting in translation of the spinal column in one or both planes (sagittal and coronal). Bony translation and shearing forces lead to disruption of the neural tissue resulting in a complete neurological

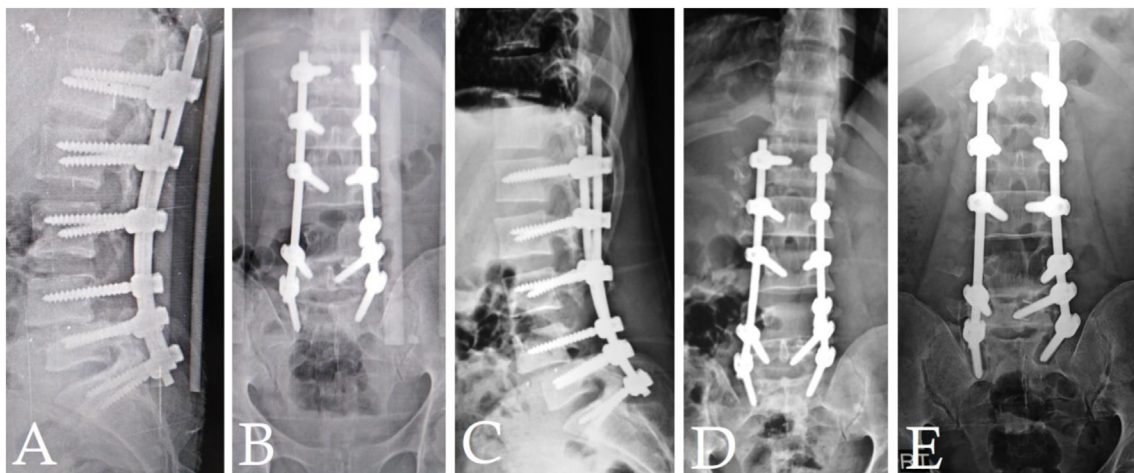


Fig. 3. Postoperative X-rays images (A,B) lateral and AP views at 6 weeks follow-up showing adequate reduction and construct, (B,C) lateral and AP views at 6 months follow-up showing stable construct, (E) AP view at 9 months follow-up showing stable construct with evidence of mobile segment in the form of halos around lower screw construct.



deficit in most cases [2]. Very rarely, these injuries can present without neurological deficits where the management presents unique difficulties to the treating surgeon. Neural tissue sparing could be due to spontaneous decompression due to pedicular fractures separating the vertebral body from the posterior arch and creating space for the neural tissue or the injury force has just fallen short of further injuring the neural tissue [3].

Fractures of the pedicles and facets dissociate the vertebral body from the posterior vertebral arch, which results in the translation of the vertebral segments. However, the neural tissue may have enough space to avoid any injury [3]. There are significant risks of further instability and neurological deficit during transfer, positioning on the operating table, and surgical intervention. Diagnosis of the injury before any dangerous maneuver to the spine is very important [4].

Due to the rarity of TLFD without neurological deficits, most cases have been previously published only as case reports. The principle of management of similar cases is the reduction and internal fixation regardless of the neurological deficit to restore the normal biomechanics and balance of the spine, achieve fusion, and avoid delayed deterioration of the neurological function [5].

Abdel-fattah and Rizk [6] reported a case of complete fracture-dislocation at L4-L5 without a neurological deficit. The body of L4 was displaced completely behind the body of L5. A fracture of the posterior arch of L5 was displaced posteriorly with L4, leading to a spontaneous decompression of the neural tissue. It was managed with open reduction and internal fixation, and the patient retained his preoperative neurological function.

Akay et al. [2] reported a case of T12-L1 fracture with lateral dislocation and without neurological deficit. The body of T12 with the spine above it was displaced laterally to the left side. The right inferior facet of T12 and the left superior facet and pedicle of L1 were fractured, causing decompression of the cord. Open reduction and internal fixation were made, and the neurological function remained intact.

Phadnis et al. [1] reported a case of L1-L2 complete fracture-dislocation in which the L2 vertebral body was dislocated laterally and to the left and had ridden up alongside the L1 vertebral body. There was a 90-degree kink in the thecal sac at the level of the fracture. There was a fracture of the left pedicle of L1 and a right pedicle of L2.

Enishi et al. [7] reported two cases of fracture-dislocation of the thoracic spine and lumbar spine with no neurological deficits. Both cases were managed by posterior laminectomy and anterior

subtotal corpectomy with reconstruction by anterior fixation device while the patients were in lateral decubitus.

Rahimizadeh et al. [4] reported a case of complete L1-L2 dislocation without a neurological deficit in which there was no fracture of the posterior arches. They described a new cord saving mechanism in which the body of L1 rotated to the left, while the posterior arch rotated to the right, with the vertebral canal being the center of rotation, avoiding any impingement of the cord. They managed the case surgically with a posterior-anterior-posterior technique. Chen [8], Smith and Love [9], Hsieh et al. [3], and Zeng et al. [5] described similar cases.

In 2021, Kanna et al. [10] published the first paper to describe the injury pathomechanics, radiological assessment, surgical techniques, principles of fixation, and classification of such cases. They classified the injury according to the direction of translation, stating the characteristics of each type and individualizing some surgical steps to take during the management of each type.

The ideal time interval for the management of these injuries remains controversial. We strongly recommend managing similar injuries as early as possible once the general condition of the patient has been stabilized. The most common cause of possible delay and negligence is the absence of a prominent neurologic deficit. Another common cause of missing the injury and delayed diagnosis of spinal injury is the presence of an associated life-threatening injury necessitating emergent intervention, particularly in polytrauma patients. Another common cause is inadequate radiologic surveys, such as failure to obtain good quality or adequate plain radiographs that may not show the spinal injury properly [5].

With delayed treatment, reduction of the displaced vertebral body can be challenging to achieve with distraction applied through the posterior approach because of the scar formed around the injury site. Furthermore, the maneuver and surgical reduction are risky and may endanger the integrity of the cord. In such circumstances, the reduction can be achieved with combined posterior and anterior surgery. After pedicle screw instrumentation and partial reduction, the patient can be flipped to the lateral decubitus for corpectomy, and the gap is replaced by a strut graft or an expandable cage. At present, in chronic cases, and with the introduction of the posterior-only procedures, posterior instrumentation, corpectomy, and cage placement can be done from posterior [4].

Adequate imaging is crucial in these cases to avoid missing the injury and adequately identify the

pattern of injury. A plain X-ray in two different planes is necessary. CT scan is almost recommended in defining the extent of the injury. Many characteristic signs can be observed on axial CT images depending on the degree of displacement. The ‘double rim’ sign is the most striking feature representing the relative displacement of one vertebral body over another, while the ‘double sun’ sign is observed in complete fracture-dislocation. Three-dimensional reconstructed CT scans are of great help in understanding the mechanism of the injury and can also assist the surgeon in correct decision-making. MRI can show the continuity of the thecal sac and, in particular, the integrity of the cord in free-floating laminae [7].

The use of intraoperative neuromonitoring (IONM) is strongly recommended in those cases to avoid further injury to the neural elements, and it should be started before placing the patient in a prone position. In our case, we did not use IONM because it was not available at that time [10].

### Conclusion

We report our experience with a case of complete L4-L5 fracture-dislocation without neurological deficit with a good clinical outcome. The absence of neurological compromise in our case could be explained by the spontaneous neurologic decompression achieved through fractures in the posterior elements. In such cases, urgent surgical intervention is of paramount importance in preserving the neurologic function and achieving good clinical results.

### Ethics Information

The article does not contain information about medical device(s)/drug(s).

### Conflict of Interest

The authors report no conflicts of interest.

### Author declaration of funding statement

No funds were received in support of this work.

### Abbreviations

CT	Computed Tomography
LV	Lumbar Vertebra
MRI	Magnetic resonance imaging
IONM	Intraoperative neuromonitoring
TLFD	Thoracolumbar fracture-dislocations
TLICS	Thoracolumbar Injury Classification and Severity Score

### References

- [1] Phadnis AS, Tan CJ, Raman AS, Crawford RJ, Rai AS. Fracture and complete dislocation of the spine with a normal motor neurology. *Inj Extra* 2006;37:479–83. <https://doi.org/10.1016/j.injury.2006.06.112>.
- [2] Akay KM, Baysefer A, Kayali H, Beduk A, Timurkaynak E. Fracture and lateral dislocation of the T12-L1 vertebrae without neurological deficit - Case report. *Neurol Med -Chir* 2003;43:267–70. <https://doi.org/10.2176/nmc.43.267>.
- [3] Hsieh CT, Chen GJ, Wu CC, Su YH. Complete fracture-dislocation of the thoracolumbar spine without paraplegia. *Am J Emerg Med* 2008;26:633. e5–633.e7. <https://doi.org/10.1016/j.ajem.2007.09.023>.
- [4] Rahimizadeh A, Asgari N, Rahimizadeh A. Complete thoracolumbar fracture-dislocation with intact neurologic function: Explanation of a novel cord saving mechanism. *J Spinal Cord Med* 2018;41:367–76. <https://doi.org/10.1080/10790268.2017.1336300>.
- [5] Zeng J, Gong Q, Liu H, Rong X, Ding C. Complete fracture-dislocation of the thoracolumbar spine without neurological deficit: A case report and review of the literature. *Medicine* 2018;97. <https://doi.org/10.1097/MD.00000000000010050>.
- [6] Abdel-Fattah H, Rizk AH. Complete fracture-dislocation of the lower lumbar spine with spontaneous neurologic decompression. *Clin Orthop Relat Res* 1990;251. <https://doi.org/10.1097/00003086-199002000-00022>.
- [7] Enishi T, Katoh S, Sogo T. Surgical treatment for significant fracture-dislocation of the thoracic or lumbar spine without neurologic deficit: A case series. *J Orthop Case Rep* 2014;4.
- [8] Chen WC. Complete fracture-dislocation of the lumbar spine without paraplegia. *Int Orthop* 1999;23. <https://doi.org/10.1007/s002640050392>.
- [9] Smith IJ, Love TW. Lower lumbar hyperextension fracture without paraplegia. *J Spinal Disord Tech* 2003;16. <https://doi.org/10.1097/00024720-200306000-00012>.
- [10] Kanna RM, Raja DC, Shetty AP, Rajasekaran S. Thoracolumbar fracture dislocations without spinal cord injury: Classification and principles of management. *Global Spine J* 2019;219256821989056. <https://doi.org/10.1177/2192568219890568>.