

Posterior Short-Segment Instrumentation with Intermediate Screw versus Long-segment Instrumentation in Thoracolumbar Fracture Treatment

Ahmed Nagaty, MD., Osama Dawood, MD., Ahmad Elsabaa, MD.

Neurosurgery Department, Faculty of Medicine, Ain Shams University, Cairo, Egypt.

ABSTRACT

Background Data: Application of either long- or short-segment instrumentation with intermediate screw to correct thoracolumbar spine fracture is still controversial. Both surgical techniques have their advantages and disadvantages. Even though early clinical results of these surgeries are usually satisfactory, a high failure rate and progressive kyphosis remain a concern.

Purpose: To assess the efficiency and safety of short-segment pedicle screw fixation in thoracolumbar junction fracture with an intermediate screw placement compared to the more popular long-segment technique.

Study Design: A retrospective comparative study

Patients and Methods: A total of 61 patients were reported in this study and divided into two groups: Group I (33 patients) in which patients were surgically treated by short-segment instrumentation with intermediate screw placement at the fractured level and Group II in which all patients were surgically treated using long-segment instrumentation excluding the fracture level (28 patients). Outcome parameters included Visual Analogue Score (VAS) score of back pain and American Spinal Injury Association (ASIA) score of neurological status.

Results: Although the VAS of back pain rapidly improved in Group I compared to Group II during the one-year follow-up, both had the same end results with no significant difference between both groups ($P > 0.05$). In Group I, the preoperative Cobb's angle was 19.3 ± 3.7 , which was corrected in the immediate postoperative X-ray to 6.8 ± 2.6 and maintained on the final follow-up at one year at 7.97 ± 1.67 . In Group II, the mean preoperative Cobb's angle was 18.7 ± 3.8 , which was corrected in the immediate postoperative X-ray to 5.8 ± 1.6 and maintained on the final follow-up at one year at 7.89 ± 1.67 . However, there was no statistically significant difference between both groups regarding angle correction ($P > 0.05$). In perioperative data, Group I showed less operative time (137.73 ± 16.96) than Group II (153.57 ± 19.525) with a highly significant statistical difference ($P < 0.001$). In addition,

Address correspondence and reprint requests: Ahmed Nagaty, MD.

Neurosurgery Department, Faculty of Medicine, Ain Shams University, Cairo, Egypt.

Email: Ahmednagaty@med.asu.edu.eg

Submitted: April 7th, 2021.

Accepted: June 13th, 2021.

Published: July 2021.

The article does not contain information about medical device(s)/drug(s).
No funds were received in support of this work.

The authors report no conflict of interest.

The editor is not included in decision or handling of this manuscript.

there was a significant statistical difference ($P < 0.05$) regarding intraoperative blood loss, as Group I (270.45 ± 35.363) showed less blood loss than Group II (292.5 ± 34.788).

Conclusion: Short-segment instrumentation with intermediate pedicle screws at the fractured level is an effective method for treating thoracolumbar junction fractures with clinical and radiological outcomes similar to those of long-segment instrumentation but with less operative time and blood loss. However, a multicenter study with long-term follow-up is highly recommended. (2021ESJ238)

Keywords: short-segment, intermediate screw, thoracolumbar fractures, trauma, spine

INTRODUCTION

Surgical treatment of thoracolumbar fractures in neurologically intact patients has shown good outcomes. Those fractures are usually unstable and require surgical stabilization to maintain reduction and kyphosis correction and promote bony fusion and early mobilization.^{20,21} The surgical approaches include the posterior approach, anterior approach, or a combination of both. The posterior approach is utilized more frequently because of its familiarity and smaller incision areas.^{12,15}

The application of either long- or short-segment construct in the management of thoracolumbar spine fracture is still controversial¹⁵. The long-segment construct is stiffer and provides good stabilization, thus minimizing the risk of posttraumatic kyphosis and screw/rods breakage. However, the main disadvantage of this technique is the loss of vertebral motion¹³. On the other hand, the short-segment construct has the advantages of a smaller surgical field, less blood loss, and reduced surgical time and hospital cost while preserving more motion segments. However, it increases the possibility of kyphosis and subsequently chronic pain and a higher incidence of instrumentation failure.^{6,8,15} In order to avoid such insufficiency with the short-segment construct, procedures supporting the anterior column have been introduced such as vertebroplasty or kyphoplasty and screws placement at the fractured vertebra.^{4,16} Many biomechanical studies^{11,12} have demonstrated that the placement of intermediate screws at the fractured vertebra can significantly increase the stiffness and stability of the construct and reduce the stress on pedicle screws, hence

preventing kyphosis progression and reducing the chance of implant failure.

A recent systematic review⁹ showed that the addition of intermediate screws results in significantly less postoperative pain, better radiological outcomes, and less implant failure. However, most differences in the outcome were small and the overall quality of the evidence was moderate to low. More studies on this topic are needed and should be directed more at patient-reported outcomes and at which specific fracture types benefit the most from intermediate screws. In this study, we aimed to compare the clinical and radiological outcomes after short-segment instrumentation with intermediate screw versus long-segment instrumentation in thoracolumbar fractures.

PATIENTS AND METHODS

This is a retrospective cohort study that included patients surgically treated for thoracolumbar spine fracture via posterior approach and transpedicular screw fixation between January 2016 and August 2020 at Ain Shams University Hospitals, Cairo, Egypt.

The protocol of our study obtained approval from the research ethics committee of our institute, Faculty of Medicine at Ain Shams University (reference number: FWA 00006444). Being a retrospective study, patients' consent for participation in the study and publication was not applicable. The study was conducted according to the WMA Declaration of Helsinki–Ethical Principles for Medical Research Involving Human Subjects.

Patients included were those with a single-level posttraumatic fracture at the thoracolumbar junction (T10-L2), with less than 50% canal compromise, local kyphosis with Cobb's angle⁵ less than 25°, type A and B injuries according to AO Spine classification¹⁹, complete contact, clinical and radiological data, and minimum 12-month follow-up. Patients with more than one level of fracture, more than 50% canal compromise, or Cobb's angle of more than 25°, osteoporosis or pathological fractures, type C injuries according to AO Spine classification, and incomplete data or follow-up and intubated patients or those with disturbed conscious level were excluded.

The included patients underwent either posterior short-segment instrumentation with intermediate screw placement at the fractured level (Group I) or long-segment instrumentation with two segments above and below the fracture vertebra, which were excluded from fixation (Group II). Allocation for either of the two techniques was according to the attending operating surgeon's preference.

Preoperative Evaluation

Clinical Evaluation. The full medical history of the patients was taken, and they were subjected to neurological assessment and general and local back examination. Preoperative evaluation of back pain severity was conducted according to the Visual Analogue Scale (VAS).⁷ On the other hand, the neurological status was documented at the time of admission, according to American Spinal Injury Association (ASIA) impairment scale² to be compared with postoperative data.

Radiological Evaluation. All patients were submitted for plain radiographs and multislice computed tomography (MSCT) scan of the spine. Radiographs were performed in both AP and lateral positions to assess the fracture characteristics and local kyphotic angle. The local kyphosis (Cobb) angle was calculated by measuring the angle between the upper endplate of the vertebra one level up and the lower endplate of the lower vertebra. MSCT scan assesses the type of fracture, degree of canal compromise, size of pedicles to choose the appropriate screw size and to assess

the integrity of the pedicles at the fractured level for screw placement. Magnetic Resonance Image (MRI) of the spine was performed for most cases to determine the neural tissue compromise, intervertebral disc affection, and integrity of the posterior ligamentous complex.

Outcome Measures: Data were collected from patients' medical records of our hospital, including the immediate postoperative period and then at 3, 6, and 12 months postoperatively. Patients' documented data included the following: assessment of pain score using VAS and neurological status using the ASIA scale. Radiological evaluation was performed by plain radiographs (AP and lateral) to assess the angle of correction and restoration of the sagittal plane, while MSCT scan to assess screws' position and decompression of the spinal canal.

Surgical Technique:

All patients were operated in a prone position under general anesthesia with endotracheal intubation. Standard midline posterior spine approach with bilateral subperiosteal muscle separation was performed in all cases. Under fluoroscopic guidance, transpedicular screw stabilization was performed in all patients who underwent either posterior bilateral short-segment pedicular screw instrumentation with bilateral intermediate screw placement at the fractured level (Group I) or bilateral long-segment pedicular screw instrumentation with two segments above and below the fractured vertebra with the exclusion of the fractured vertebra from fixation (Group II). Posterolateral fusion was performed using bone fragments and autologous bone graft through either decompressed bone or iliac crest graft. Single-level laminectomy was done only when there were neurological deficits due to cord contusion or with retropulsed segment occupying more than 40% of the spinal canal on CT scan. Examples and case demonstrations are demonstrated in Figures 1 and 2.

Statistical Analysis:

Data were analyzed using Statistical Program for Social Science (SPSS). Quantitative data

were expressed as mean \pm standard deviation (SD). Moreover, qualitative data were expressed as frequency and percentage. Independent sample *t*-test of significance, paired sample *t*-test

of significance, and probability (P-value) were used. P-value < 0.05 was considered significant, P-value < 0.001 was considered highly significant, while P-value > 0.05 was considered insignificant.

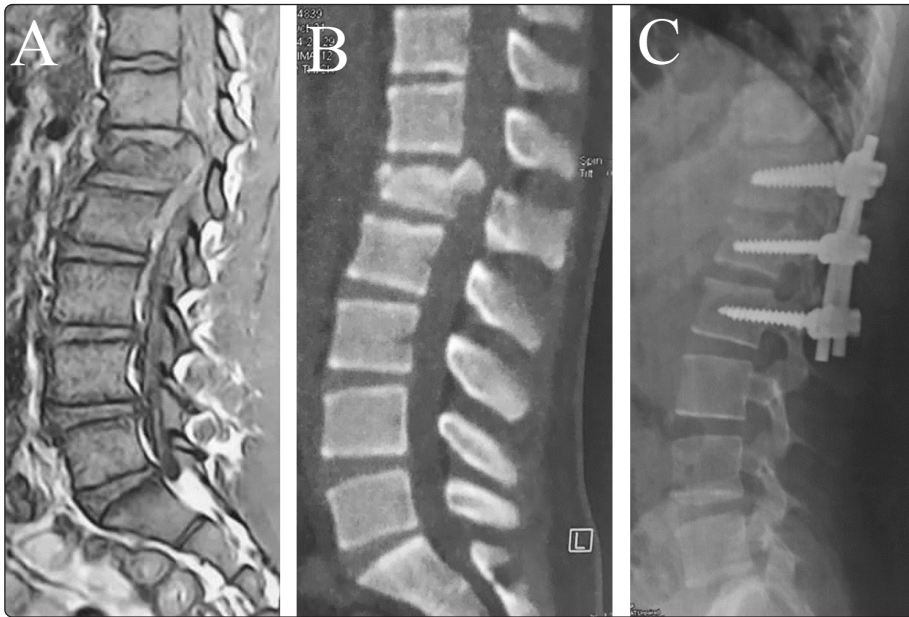


Figure 1.

Male patient with L1 burst fracture. (A) Preoperative sagittal T1 MRI. (B) Preoperative sagittal CT scan. (C) Postoperative plain radiograph lateral view showing T12-L2 fixation short-segment fixation.

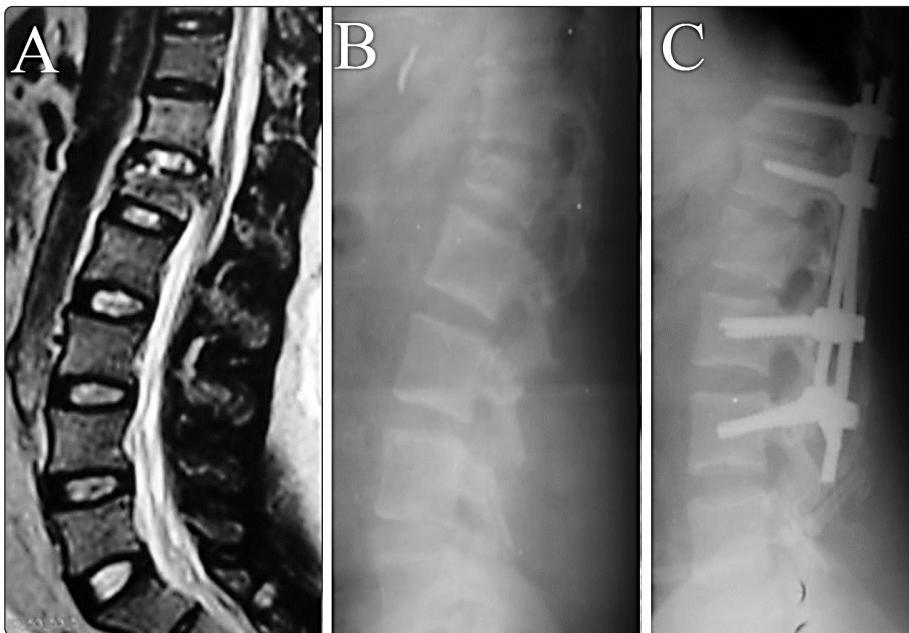


Figure 2.

Male patient with L1 burst fracture. (A) Preoperative sagittal T2 MRI. (B) Preoperative plain radiograph lateral view. (C) Postoperative plain radiograph lateral views showing T12-L3 long-segment fixation.

RESULTS

This retrospective study reported 61 patients diagnosed with single-level thoracolumbar AO Spine type A or B fracture. Patients were divided into two groups: short-segment fixation (Group I)

with a total number of 33 patients (54%) and long-segment fixation (Group II) of 28 patients (46%). There were 53 males (87%) and 8 females (13%) with a mean age at time presentation of 38 ± 9.2 (29–47) years, with no statistical difference between both study groups regarding demographic data (age and sex).

The most common mode of trauma in both groups was falling from height (62.3%), followed by road traffic accidents (RTA) (37.7%). The most common level of thoracolumbar vertebrae fracture for the entire cohort was L1 (37.7%), followed by L2 (29.6%) and D12 (23%), with the least incidence in D11 (6.6%). Regarding types of fractures, they were variable, with the most common fracture being burst fracture (Type A3 and A4 fractures according to AO Spine morphological classification system) (42.6%) and compression fracture (Type A2 fractures) (28%), while the remaining cases were type B fractures (29.4%). Both groups showed no statistical difference regarding the mode of trauma and type of fracture.

With regard to neurological status, most cases in both Group I (81%) and Group II (82%) were ASIA E, with no statistically significant difference between the two groups in preoperative and postoperative ASIA scores ($P > 0.05$) (Table 1).

The perioperative data, including operative time and blood loss, number of patients who had laminectomy during fixation, hospital stay, and follow-up period, is summarized in Table 2. Statistical analysis showed that there was a highly significant statistical difference ($P < 0.001$) between both groups regarding operative time, with less time needed in Group I (137.73 ± 16.96) than that in Group II (153.57 ± 19.525). In addition, there was a significant statistical difference ($P < 0.05$) in terms of intraoperative blood loss, as Group I (270.45 ± 35.363) showed less blood loss than Group II (292.5 ± 34.788). However, other parameters showed no statistically significant difference between both groups (Table 2).

The mean preoperative VAS of back pain for Group I (short-segment construct) was 5.6 ± 2.1 and improved to 2.9 ± 1.47 at six months and 1.39 ± 0.56 at the one-year final follow-up. In Group II (long-segment construct), the mean preoperative VAS of back pain was 5.8 ± 2.2 and improved to 3.96 ± 1.43 at the six-month follow-up and 1.82 ± 0.48 at the end of the first

postoperative year. Although the VAS of back pain rapidly improved in Group I compared to that of Group II during the one-year follow-up, both had nearly the same end results and there was no statistically significant difference between both groups regarding pain scales by the end of the first postoperative year with P -value

In Group I, the mean preoperative Cobb's angle was $19.3 \pm 3.7^\circ$, which was corrected in the immediate postoperative radiographs to $6.8 \pm 2.6^\circ$ and maintained on the final follow-up at one year at $7.97 \pm 1.67^\circ$. In Group II, the mean preoperative Cobb's angle was $18.7 \pm 3.8^\circ$, which was corrected in the immediate postoperative X-ray to $5.8 \pm 1.6^\circ$ and maintained on the final follow-up at one year at $7.89 \pm 1.67^\circ$. However, there was no statistically significant difference between short-segment fixation and long-segment fixation with regard to angle correction, using an independent sample t -test with P -value > 0.05 (Table 3).

No intraoperative complications were reported in all our study cases of both groups, except for 2 cases of dural tear during laminectomy (one case in each group), that were managed intraoperatively by direct suturing of the dura with an application of muscle graft, while no postoperative CSF collection or leak was detected in these two cases. Regarding postoperative complications, only mild superficial wound infection was detected in 3 cases (one case in Group I and two cases in Group II), which was managed conservatively with local antibiotics and frequent dressings.

DISCUSSION

In our study, two patient groups underwent surgical treatment of thoracolumbar junction fracture, Group I (short-segment instrumentation with intermediate screw) and Group II (long-segment instrumentation). The demographic, clinical, and radiological properties were homogenous with no statistically significant difference. The measured outcomes of both groups, especially pain scores, kyphotic angle correction, and neurological

Table 1. Preoperative data of the study patients.

Parameters		Group I	Group II	P-value
No. of cases		33 (54%)	28 (46%)	
Age/years		36 ± 7	39 ± 8	0.1236
Sex	Male	28 (85%)	25 (89%)	0.7155
	Female	5 (15%)	3 (11%)	
Type of trauma	RTA	13 (40%)	10 (36%)	0.883
	Falls	20 (60%)	18 (64%)	
AO Spine Classification	Type A	23 (70%)	20 (71%)	>0.999
	Type B	10 (30%)	8 (29%)	
Level of fracture	D11	4 (12%)	2 (7%)	0.81
	D12	8 (24.5%)	6 (21%)	
	L1	13 (39%)	10 (36%)	
	L2	8 (24.5%)	10 (36%)	
Neurological status	ASIA D	6 (19%)	5 (18%)	>0.999
	ASIA E	27 (81%)	23 (82%)	

Table2. Perioperative data of the study patients.

Parameters	Group I	Group II	P-value
Operative time/minutes	137.73 ± 16.96	153.57 ± 19.525	0.001
Operative blood loss/ml	270.45 ± 35.363	292.5 ± 34.788	0.017
Performed laminectomy	3 (9.1%)	5 (17.9%)	0.312
Hospital stay/days	3.61 ± 0.704	3.79 ± 0.686	0.318
Follow-up period/months	14.27 ± 0.761	14.25 ± 0.799	0.91

Table 3. Comparison of spinal Cobb's angle at different follow-up points in both groups.

Kyphotic angle		Group I	Group II	P-value
Preoperative		19.3 ± 3.7	18.68 ± 3.82	0.52
	Immediate	6.8 ± 2.6	5.8 ± 1.6	0.098
	3 months	7.85 ± 1.8	7.46 ± 1.86	0.419
Postoperative	6 months	8 ± 1.85	7.8 ± 1.83	0.7
	9 months	8 ± 1.96	8.07 ± 2.16	0.971
	1 year	7.9 ± 1.67	7.89 ± 1.87	0.86

status, were similar with no statistically significant difference.

The clinical application of the pedicle screw at the fractured vertebrae "intermediate screw" for thoracolumbar fractures is controversial due to the limited evidence available. Later, some in vitro biomechanical studies on the pedicle screw

at the fracture level showed that it could clearly improve the stability of the pedicle screw fixation system and decrease the stress distribution on each pedicle screw.¹⁴

Some authors¹³ also suggested that pedicle screw fixation combined with an intermediate screw at the fractured vertebrae improved biomechanical

stability and achieved better reduction, less correction loss, fewer instrument failures, and comparable or better clinical outcomes. Anekstein et al.¹ concluded that the addition of intermediate screws significantly increased the strength of a short-segment pedicular fixation. In a human cadaveric study, Mahar et al.¹³ showed that axial torsion stability improved twofold with intermediate screws, especially in flexion-extension and lateral bending. Biomechanically, the “intermediate” screws can function as a push point with an anterior vector, creating a “lordorizing” force that also corrects kyphosis. The three-point fixation afforded decreases the cantilever effects that cause kyphosis.⁸

Dick et al.³ reported that the additional insertion of pedicle screws at the fractured level improves biomechanical stability by supporting the anterior column and diminishing stress on each pedicle screw.¹⁶ controversy remains regarding the effectiveness of cross-linking and the necessity of placing pedicle screws at the intermediate levels of the segment to be fused. The purpose of this study is to evaluate the stiffness of various rod/screw constructs used to instrument a three-level fusion with specific emphasis on the effect of cross-linking and the intermediate pedicle screws. Nine lumbar calf spines were mounted at L1 and L5. Pedicle screws (TSRH, Danek, Memphis, TN) Moreover, in their study, Guven et al.⁶ showed that better correction was achieved in short-segment applications combined with a screw placed at the fracture level than short-segment fixations without intermediate screw.

Pellise et al.¹⁷ examined 72 patients who underwent a six-screw construct for thoracolumbar burst fracture and noted no implant failure. While a study done by Dobran et al.⁴ showed that short-segment fixation with intermediate screws provides radiological results similar to long-segment posterior fixation in which two levels above and two levels below the fracture are fixated. However, a short-segment 6-screw construct could

decrease the size of the immobilized segment and therefore retain more spinal motion than a long-segment fixation.¹⁰

The present study confirms that intraoperative fracture reduction and correction of kyphotic angle in patients with thoracolumbar junction fractures can be achieved by short-segment instrumentation with the placement of intermediate screws in the fractured level with good clinical and radiological outcomes comparable to long-segment instrumentation. Moreover, short-segment instrumentation with intermediate screws can save two or more segments of vertebral motion compared to long-segment construct.

There are some limitations to our study. First, this study is a retrospective study done in a single institute. Second, patients' allocation was not random but according to the surgeon's preference. Third, the sample size is small and lacks long-term follow-up. Thus, a multicenter comparative study with a long-term follow-up is recommended to establish the obtained results. Recently, AO Spine developed patient-reported outcome measures specific for trauma. This AO Spine PROST is considered a valuable tool for use in the clinical setting and research. It can contribute to the reduction of ongoing controversies in spine trauma care when used in a global setting, allowing us to compare different treatment options in a valid and reliable fashion.¹⁸

CONCLUSION

Short-segment instrumentation with intermediate pedicle screws at the fractured level is an effective method for the treatment of thoracolumbar junction fractures with clinical and radiological outcomes like long-segment instrumentation. Moreover, short-segment instrumentation with intermediate screws can save two segments of vertebral motion, with less operative time and blood loss. However, a multicenter study with long-term follow-up is highly recommended.

REFERENCES

1. Anekstein Y, Brosh T, Mirovsky Y: Intermediate screws in short segment pedicular fixation for thoracic and lumbar fractures: a biomechanical study. *J Spinal Disord Tech* 20:72–77, 2007
2. Bizhan A, Charles A, David M, J. Marc S, David S, Elizabeth L, et al: Intramedullary lesion length on postoperative magnetic resonance imaging is a strong predictor of Asia impairment scale grade conversion following decompressive surgery in cervical spinal cord injury. *Danesh Neurosurgery* 80(4):610–620, 2017
3. Dick JC, Jones MP, Zdeblick TA, Kunz DN, Horton WC: A biomechanical comparison evaluating the use of intermediate screws and cross-linkage in lumbar pedicle fixation. *J Spinal Disord* 7:402–407, 1994
4. Dobran M, Nasi D, Brunozzi D, di Somma L, Gladi M, Iacoangeli M, et al: Treatment of unstable thoracolumbar junction fractures: short-segment pedicle fixation with inclusion of the fracture level versus long-segment instrumentation. *Acta Neurochir (Wien)* 158:1883–1889, 2016
5. Giannoglou V, Stylianidis E: Review of advances in Cobb angle calculation and image-based modeling techniques for spinal deformities, in *Proceedings of Isprs Annals of Photogrammetry, Remote Sensing and Spatial Information Sciences*, Vol. 3-5, pp 12–19, 2016
6. Guven O, Kocaoglu B, Bezer M, Aydin N, Nalbantoglu U: The use of screw at the fracture level in the treatment of thoracolumbar burst fractures. *J Spinal Disord Tech* 22:417–421, 2009
7. Jensen MP, Chen C, Brugger AM: Interpretation of visual analog scale ratings and change scores: a reanalysis of two clinical trials of postoperative pain. *J Pain* 4:407–414, 2003
8. Kanna RM, Shetty AP, Rajasekaran S: Posterior fixation including the fractured vertebra for severe unstable thoracolumbar fractures. *Spine J Off J North Am Spine Soc* 15:256–264, 2015
9. Kapoen, C, Liu, Y, Bloemers, Deunk J: Pedicle screw fixation of thoracolumbar fractures: conventional short segment versus short segment with intermediate screws at the fracture level - A systematic review and meta-analysis. *Eur Spine J* 29, 2491–2504, 2020
10. Li J, Liu L: Comparison of short segment versus long segment fixation for the treatment of thoracolumbar burst fracture: a meta-analysis. *Int J Clin Exp Med* 10:1750–1762, 2017
11. Li K, Zhang W, Liu D, Xu H, Geng W, Luo D, et al: Pedicle screw fixation combined with intermediate screw at the fracture level for treatment of thoracolumbar fractures: A meta-analysis. *Medicine (Baltimore)* 95: e4574, 2016
12. Liao J-C, Fan K-F: Posterior short-segment fixation in thoracolumbar unstable burst fractures - Transpedicular grafting or six-screw construct? *Clin Neurol Neurosurg* 153:56–63, 2017
13. Mahar A, Kim C, Wedemeyer M, Mitsunaga L, Odell T, Johnson B, et al: Short-segment fixation of lumbar burst fractures using pedicle fixation at the level of the fracture. *Spine* 32:1503–1507, 2007
14. Norton RP, Milne EL, Kaimrajh DN, Eismont FJ, Latta LL, Williams SK: Biomechanical analysis of four- versus six-screw constructs for short-segment pedicle screw and rod instrumentation of unstable thoracolumbar fractures. *Spine J* 14(8):1734–1739, 2014
15. Ökten Ai, Gezercan Y, Özsoy KM, Ateş T, Menekşe G, Aslan A, et al: Results of treatment of unstable thoracolumbar burst fractures using pedicle instrumentation with and without fracture-level screws. *Acta Neurochir (Wien)* 157:831–836, 2015

16. Ozdemir B, Kanat A, Erturk C, Batcik OE, Balik MS, Yazar U, et al: Restoration of anterior vertebral height by short-segment pedicle screw fixation with screwing of fractured vertebra for the treatment of unstable thoracolumbar fractures. *World Neurosurg* 99:409–417, 2017
17. Pellisé F, Barastegui D, Hernandez-Fernandez A, Barrera-Ochoa S, Bagó J, Issa-Benítez D, et al: Viability and long-term survival of short-segment posterior fixation in thoracolumbar burst fractures. *Spine J Off J North Am Spine Soc* 15:1796–1803, 2015
18. Sadiqi S, Dvorak M, Vaccaro A, Schroeder G, Marcel W, Benneker, L, et al: Reliability and validity of the English version of the AOSpine PROST (Patient Reported Outcome Spine Trauma), *Spine* 45(17):E1111–E1118, 2020
19. Schuld C, Franz S, Bruggerman K, Heutehaus L, Weidner N, Kirshblum SC, et al: International standards for neurological classification of spinal cord injury: impact of the revised worksheet (revision 02/13) on classification performance. *J Spinal Cord Med* 39(5):504–512, 2016
20. Siebenga J, Leferink VJM, Segers MJM, Elzinga MJ, Bakker FC, Haarman HJTM, et al: Treatment of traumatic thoracolumbar spine fractures: a multicenter prospective randomized study of operative versus nonsurgical treatment. *Spine* 31:2881–2890, 2006
21. Thanappan N, Saravanamuthu T, Singaravel, Sivakaran: Functional analysis of effectiveness of short segment with index vertebra fixation as compared with long-segment fixation in the management of thoracolumbar spinal injuries. *Int J Sci Stud* 6(12):146–150, 2019

LIST OF ABBREVIATIONS:

- RTA: Road traffic accident.
MSCT: Multislice computerized tomography
MRI: Magnetic resonance images
VAS: Visual analogue score
ASIA score: American Spinal Injury Association score.

الملخص العربي

علاج كسور الفقرات الصدرية القطنية؛ دراسة مقارنة بين تثبيت الفقرات قصير المقطع متضمناً مستوي الكسر والتثبيت طويل المقطع.

البيانات الخلفية: عند استخدام التدخل الجراحي الخلفي لإصلاح كسور الفقرات الصدرية القطنية، يظل استخدام التثبيت قصير المقطع أو طويل المقطع محل خلاف، فإن التثبيت طويل المقطع (متضمناً مستويين أعلى وأسفل مستوي الكسر) هو أقوى ويساعد على ثبات جيد للفقرات، ويقلل من فرص انحناء العمود الفقري أو انكسار مسامير التثبيت. على الجانب الآخر؛ فإن التثبيت قصير المقطع (متضمناً مستوي واحد أعلى وأسفل مستوي الكسر) له أفضلية التدخل المحدود وفقدان نسب دم أقل، وتقليل وقت الجراحة وتكلفة المستشفى مع الحفاظ على أجزاء متحركة أكثر بالعمود الفقري.

الغرض: تقييم مدى فاعلية وأمان استخدام التثبيت قصير المقطع متضمناً تثبيت مستوي الكسر لإصلاح كسور الفقرات الصدرية القطنية.

تصميم الدراسة: تحليل بأثر رجعي لسلسلة من الحالات.

المواد والطرق: تضمنت الدراسة حالات مصابة بكسر الفقرات الصدرية القطنية والتي تمت علاجها عن طريق تثبيت الفقرات باستخدام التدخل الجراحي الخلفي في الفترة من يناير ٢٠١٦ إلى أغسطس ٢٠٢٠ وذلك بمستشفيات جامعة عين شمس. وقد تقسيم تلك الحالات إلى مجموعتين؛ مجموعة (أ) (٣٣ حالة) وقد تم علاجها بتثبيت الفقرات قصير المقطع متضمناً تثبيت مستوي الكسر، ومجموعة (ب) (٢٨ حالة) تم علاجها بتثبيت الفقرات طويل المقطع.

النتائج: علي الرغم من التحسن السريع في معدلات آلام الظهر في المجموعة (أ) أثناء فترة المتابعة الأولية مقارنةً بالمجموعة (ب)؛ إلا أنه لم يكن هناك فارق مؤثر في معدل الألم بين المجموعتين مع نهاية العام الأول من المتابعة. أما النتائج الخاصة بتعديل زاوية (كوب) بعد التدخل الجراحي؛ فلم يكن هناك أيضاً فارق مؤثر بين المجموعتين خلال فترة المتابعة.

الخلاصة: إن استبدال زاوية إنحناء العمود الفقري جراحياً في حالات كسور الفقرات الصدرية القطنية من الممكن تحقيقه عن طريق تثبيت الفقرات قصير المقطع متضمناً تثبيت مستوي الكسر مع تحقيق نتائج جيدة إكلينيكيًا وعلى مستوي الأشعات، مقارنةً بالتثبيت طويل المقطع، وإن كان للتثبيت قصير المقطع أفضلية توفير مستوي أو مستويين متحركين بالعمود الفقري.