

# Long-Term Outcomes After Four-Level Cervical Arthrodesis with Stand-Alone PEEK Cage versus PEEK Cage with Anterior Plating: A Retrospective Multicenter Comparative Study

Walid Abouzeid, MD.<sup>1</sup>, Momen M Almamoun, MD.<sup>1</sup>, Tamer Niazy, MD.<sup>2</sup>, Mohamed G Abdel Tawab MD.<sup>3</sup>

1 Neurosurgery Department, Sohag University, Sohag, Egypt.

2 Orthopedic surgery Department, Mansoura University, Mansoura, Egypt.

3 Neurosurgery Department, Fayoum University, Fayoum, Egypt.

## ABSTRACT

**Background Data:** Anterior cervical discectomy and fusion (ACDF) is a gold-standard option for treating cervical degenerative disc diseases (DDD). Anterior plating enhances stabilization with improved outcomes and reduced risk of pseudarthrosis yet with annoying morbidities. Fusion with stand-alone cages avoids such complications, although its use in multilevel disc arthrodesis is still controversial.

**Study Design:** Retrospective multicenter comparative cohort study.

**Purpose:** To evaluate clinical and radiological long-term outcomes after ACDF with stand-alone polyetheretherketone (PEEK) cages versus ACDF with cages and plating.

**Patients and Methods:** Patients who underwent four-level stand-alone ACDF (Group 1) or ACDF with plating (Group 2) between July 2012 and May 2016 and followed up for at least two years were recruited for this study. In this study, the reported outcome parameters included operative time, operative blood loss, fusion rate, cervical curve, neck disability index (NDI), Visual Analogue Score (VAS) of neck pain, patient satisfaction, and perioperative morbidity.

**Results:** Forty-seven patients, including 25 males and 22 females, were reported. The mean age was 50.8 and 50.1 years in Groups 1 and 2, respectively. Twenty-four patients underwent stand-alone ACDF and 23 underwent ACDF with plating. The baseline characteristics data of both groups were homogeneous between groups. The outcome parameters (NDI, cervical curve VAS scores, fusion rate, complications, reoperation rate, and patient satisfaction) showed no significant difference between the two groups at different time points of follow up. Pre- and postoperative NDI and VAS showed significant improvement in both groups. Dysphagia was reported more frequently in Group 2.

**Conclusion:** Four-level ACDF with stand-alone PEEK cage is equally effective as ACDF with anterior plating in patients treated for four-level cervical DDD with less incidence of dysphagia. (2021ESJ233)

**Keywords:** ACDF, cervical disc disease, 4-level cervical disc, NDI, cervical curve, fusion rate.

Address correspondence and reprint requests: Walid KA Abouzeid, MD.

Neurosurgery Department, School of Medicine, Suhag university, Naser city, Sohag,82524, Egypt.

Email: Walidneuro8@yahoo.com

Submitted: February 7<sup>th</sup>, 2021.

Accepted: March 20<sup>th</sup>, 2021.

Published: April 2021.

The article does not contain information about medical device(s)/drug(s).

No funds were received in support of this work.

The authors report no conflict of interest.

The editor is not included in decision or handling of this manuscript.

## INTRODUCTION

Cervical degenerative disc disease (DDD) is a major and global health problem with a significant socioeconomic burden. Although most patients are treated conservatively, surgery may be considered in some patients. Since its description in the 1950s, anterior cervical discectomy and fusion (ACDF) is considered a gold-standard option for managing cervical DDD when conservative management fails and in patients with progressive neurological deficits.<sup>7,4</sup> Over the past decades, many technical procedures have been described, including ACDF using bone autograft, allograft, plating, PEEK cages, and other fusion techniques.<sup>1</sup> ACDF provides long-term stabilization, maintains disc height, and allows proper decompression.<sup>6</sup> Anterior plating has been considered to allow more segment stabilization with improved outcomes and reduced risk of pseudarthrosis.<sup>14</sup> However, using anterior plating is not devoid of complications; one of its common and annoying complications is dysphagia, which may be permanent.<sup>15</sup> As a result, stand-alone ACDF was proposed as an alternative that reduces postoperative dysphagia in multilevel ACDF.<sup>17</sup> Multilevel stand-alone ACDF may be associated with some morbidity, including pseudoarthrosis, subsidence, and extrusion.<sup>9,16</sup> Until now, there is no consensus and there is ongoing controversy regarding the use of stand-alone ACDF versus ACDF with plating in patients with a multilevel cervical disc.

This study aims to compare retrospectively the clinical and radiological long-term outcomes of patients who underwent 4-level stand-alone ACDF versus ACDF with plating in patients with cervical DDD.

## PATIENTS AND METHODS

In this multicenter retrospective cohort study, all patients with complete data who underwent four-level ACDF with or without anterior cervical

plate between July 2012 and May 2016 at the neurosurgical centers of Suhag, Mansoura, and Fayoum University Hospitals were enrolled in this study. The medical records of our three institutional hospitals were reviewed for all patients who underwent ACDF. All patients between 36 and 65 years old, who failed adequate conservative therapy, with radiologically confirmed multilevel cervical DDD, treated with either four-level stand-alone ACDF or with ACDF and plating, with complete contact, clinical, radiological data, and with at least two-year follow-up were reported. Patients with a history of trauma, developmental spinal canal stenosis, history of previous cervical spine surgery, tumor, infection, severe osteoporosis, posterior longitudinal ligament ossification, chronic rheumatic disease, and incomplete data records were excluded from this study. Patients' allocation to either Group 1 or Group 2 was at the preference of the attendant surgeon. All patients formally consented before the index surgery.

The study was conducted after the approval of our three institutional review boards (IRB) and written informed consent was obtained from each patient or their legal guardians. The study was conducted according to the WMA Declaration of Helsinki–Ethical Principles for Medical Research Involving Human Subjects.

At the time of the index surgery, all patients were submitted for full clinical and radiological evaluation. Radiological evaluation included MRI of the cervical spine and plain radiographs in AP and lateral views and dynamic study.

Preoperative clinical parameters included age, sex, BMI, NDI, and neck pain VAS, while radiographic parameters included cervical curve. The cervical curve was assessed using C2–C7 Cobb's angle in a neutral position, from the inferior endplate of C2 to the inferior endplate of C7. Operative parameters included operative time and blood loss; postoperative parameters included NDI, neck pain VAS, patient satisfaction, fusion rate, cervical curve, and morbidity, including dysphagia and reoperation. Patient satisfaction was assessed

subjectively as excellent, good, fair, or poor at the last reported follow-up visit.

Patients were submitted for routine plain radiographic evaluation on each clinical visit, while CT scans were used in case of reporting any abnormal event, including persistent neck pain or suspected plain radiographic sign. Cervical fusion was assessed using the Bridwell grading system.<sup>2,10</sup> According to the routine postoperative follow-up protocol, which was similar in the three centers, all patients were scheduled for outpatients' visits at 1, 3, and 6 months, then at 6-month intervals.

#### **Surgical Technique:**

Operations were conducted under general anesthesia in the supine position with either a right- or left-side anterior cervical approach, according to the surgeon's preference. After fluoroscopy-guided disc exposure, adequate neural decompression, including removal of disc hernia, posterior longitudinal ligament, osteophytes, and any other compressive elements, was conducted. Cartilaginous endplates were removed carefully through curettage to preserve the bony endplates to avoid cage subsidence. In Group 1, we used stand-alone PEEK cages (EgiFix™, Egypt) without plating, whereas in Group 2, we used the same cage with anterior plates (EgiFix™, Egypt). Cages were implanted at a size of 4–7 mm in height according to the level and the preoperative disc height. The chosen cages were at least 1 mm higher than the affected discs. During surgery, cage trials and lateral fluoroscopy also helped with this issue. Bone graft substitutes (Zimmer Biomet™) were inserted into the cages to conduct fusion. The length of the needed plate was estimated using lateral fluoroscopy, and the screws were introduced in a cross way, and the length of the screws was checked by the fluoroscopy. Then, the plate was locked, a closed system wound drain was inserted, and after meticulous hemostasis, the wound was closed in layers. After surgery, all patients had to undergo physical rest for six weeks, followed by physiotherapy. A cervical collar was applied for six weeks. Most patients were discharged from the hospital on the second

postoperative day. Patients were scheduled for routine outpatient clinic follow-up.

#### **Statistical Analysis:**

Descriptive statistics were presented as mean (SD) for normally distributed numeric variables, while they were presented as median (IQR) for nonnormally distributed numeric variables and frequencies and percentages for categorical variables. Comparison of the two groups was made using an independent sample *t*-test for normally distributed numeric variables and using the Mann–Whitney *U* test for nonnormally distributed numeric variables or ordinal variables. For categorical variables, the chi-square test and Fisher's exact test were used. IBM SPSS statistics software, version 26, was used for the analysis and *p* value < 0.05 was considered statistically significant. Friedman's test was used to study if there is a change in the NDI at different time points. *P*-values for the pairwise comparisons using Bonferroni adjustment were reported.

## RESULTS

The medical records of 206 patients who underwent multilevel ACDF between July 2012 and May 2016 at the included centers were revised. Of the 64 patients who underwent four-level ACDF, 47 patients were eligible for the study after exclusion of the records of 17 patients due to incomplete data, contact details, follow-up. Twenty-four patients underwent four-level stand-alone ACDF (Group 1) and 23 patients underwent ACDF with plating (Group 2). All patients completed at least two-year follow-up and 5 years at maximum with mean follow-up of  $3.5 \pm 1.1$  (2–5) years.

The baseline characteristics including age, sex, and BMI did not differ significantly between both groups. Also, the preoperative cervical curve, NDI, and VAS scores for neck pain showed no difference between both groups (Table 1). No significant differences were observed between the two groups when comparing different preoperative

epidemiological variables (Table 1). In terms of the preoperative parameters, intergroup comparisons of the NDI, cervical curve, and VAS values for pain indicated no significant difference between both groups. At two years and the last follow-up, VAS values in both groups showed no changes.

Compared to the preoperative values, the postoperative NDI improved at various time periods in both groups. At three months, there was no difference; however, at six months and the last follow-up, substantial changes in NDI were reported (Table 2). Moreover, the cervical curve showed improvement at different time points in both groups compared to the preoperative

measurement. Changes were substantial at three months and six months; however, at the last follow-up, they were insignificant (Table 2, Figure 1). VAS scores for pain showed significant improvement at different time points when compared to the preoperative measures and each other; however, the last follow-up measurement showed no significant changes when compared to the six-month measurement (Table 2, Figure 2). We did not report significant differences between the two groups regarding fusion rate at both one-year, two-year, and last follow-up (Table 3). Four case presentations are demonstrated in Figures 3–6.

**Table 1.** Baseline characteristics of the two groups.

Variables	Group 1 (N = 24)	Group 2 (N = 23)	P value
Age/years	50.8 ± 8 (37–63)	50.1 ± 8.4 (36–65)	0.756
BMI	25.5 ± 4.5 (20–36)	27.2 ± 4.2 (2–35)	0.206
Sex: male/female	13/11	12/11	0.891

An independent sample *t*-test was used for age. BMI; body mass index.

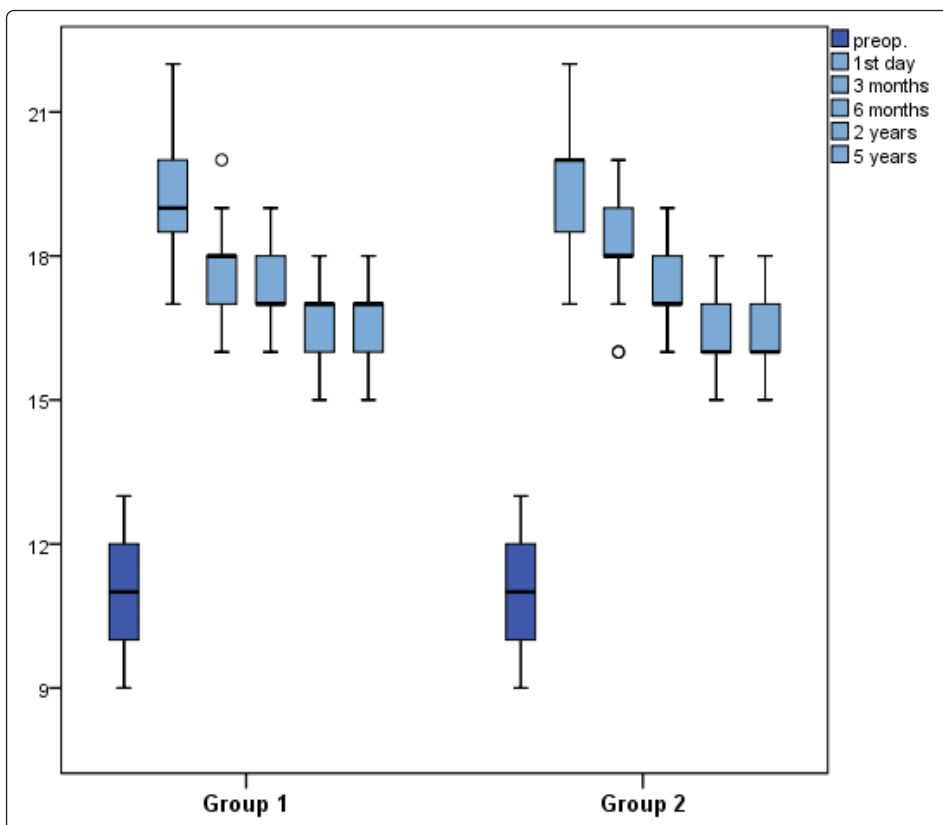
**Table 2.** Comparison of pre and postoperative outcomes:

Variables	Group 1			Group 2			P value
	Mean ± SD (range)	Median	IQR	Mean ± SD	Median	IQR	
Cervical curve							
Preoperative	10.8 ± 1.3 (9–13)	11.00	2	10.7 ± 1.3 (9–13)	11.00	2	0.878
3 months	17.9 ± 0.9 (16–20)	18.00	1	18.1 ± 1 (16–20)	18.00	1	0.279
6 months	17.3 ± 0.8 (16–19)	17.00	1	17.4 ± 0.9 (16–19)	17.00	1	0.596
2 years	16.6 ± 1 (15–18)	17.00	1	16.5 ± 0.8 (15–18)	16.00	1	0.631
Last follow-up	16.6 ± 1 (15–18)	17.00	1	16.5 ± 0.8 (15–18)	16.00	1	0.631
NDI							
Preoperative	33.7 ± 2.3 (29–38)	34.00	3	33 ± 2.9 (28–39)	33.00	4	0.319
3 months	18.5 ± 1.8 (15–22)	18.00	3	18 ± 1.8 (15–20)	18.00	4	0.480
6 months	16.9 ± 1.6 (15–20)	17.00	3	16.3 ± 1.3 (14–18)	16.00	3	0.227
2 years	15.1 ± 1.1 (14–17)	15.00	1.75	14.9 ± 0.7 (14–16)	15.00	1	0.714
Last follow-up	15.1 ± 1.1 (14–17)	15.00	1.75	14.9 ± 0.7 (14–16)	15.00	1	0.714
VAS							
Preoperative	7.3 ± 1.4 (5–10)	7.00	2	7.1 ± 1.3 (5–10)	7.00	2	0.662
3 months	2.4 ± 1.2 (0–4)	2.00	1	2.2 ± 1.3 (0–5)	2.00	2	0.569
6 months	0.5 ± 0.7 (0–2)	0.00	1	0.4 ± 0.7 (0–2)	0.00	1	0.340
2 years	0.0 ± 0.0 (0–0)	0.00	0	0.0 ± 0.0 (0–0)	0.00	0	–
Last follow-up	0.0 ± 0.0 (0–0)	0.00	0	0.0 ± 0.0 (0–0)	0.00	0	–
Operative time	136.3 ± 14.7 (120–170)	140.00	20	139.6 ± 16.6 (120–170)	140.00	30	0.461
Blood loss	268.8 ± 106.1 (150–500)	225.00	137.5	271.7 ± 98.7 (150–500)	250.00	100	0.727

BMI, chi-square test used for sex while Mann–Whitney test was used for preoperative cervical curve, NDI, and VAS.

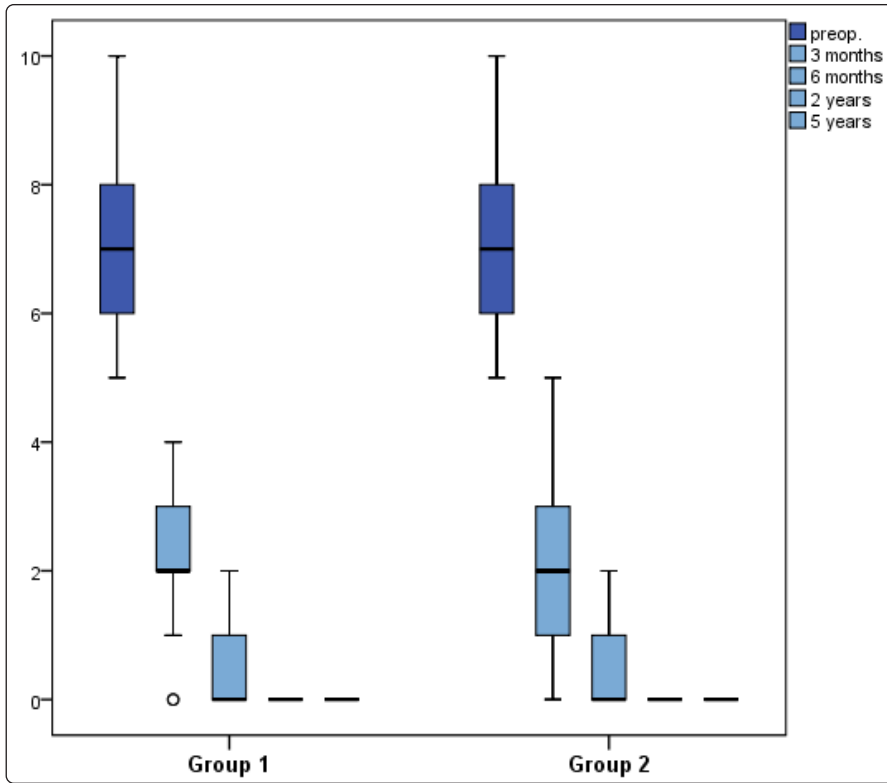
**Table 3.** Comparison of surgical outcomes, complications, and patient satisfaction in both groups.

Parameters		No-plate group	Plate group	P value
Fusion at 1 year	Certain	20 (83.3%)	18 (78.3%)	0.724
	Doubtful	4 (16.7%)	5 (21.7%)	
Fusion at 2 years	Certain	24 (100.0%)	23 (100.0%)	–
Fusion at 5 years	Certain	24 (100.0%)	23 (100.0%)	–
Dysphagia	No	24 (100.0%)	13 (56.5%)	<0.001
	Yes	0 (0.0%)	10 (43.5%)	
Infection	Yes	1 (4.2%)	1 (4.3%)	>0.999
	No	23 (95.8%)	22 (95.7%)	
Satisfaction	Excellent	15 (62.5%)	10 (43.5%)	0.185
	Good	8 (33.3%)	8 (34.8%)	
	Poor	1 (4.2%)	5 (21.7%)	
Reoperation	No	22 (91.7%)	21 (91.3%)	>0.999
	Yes	2 (8.3%)	2 (8.7%)	

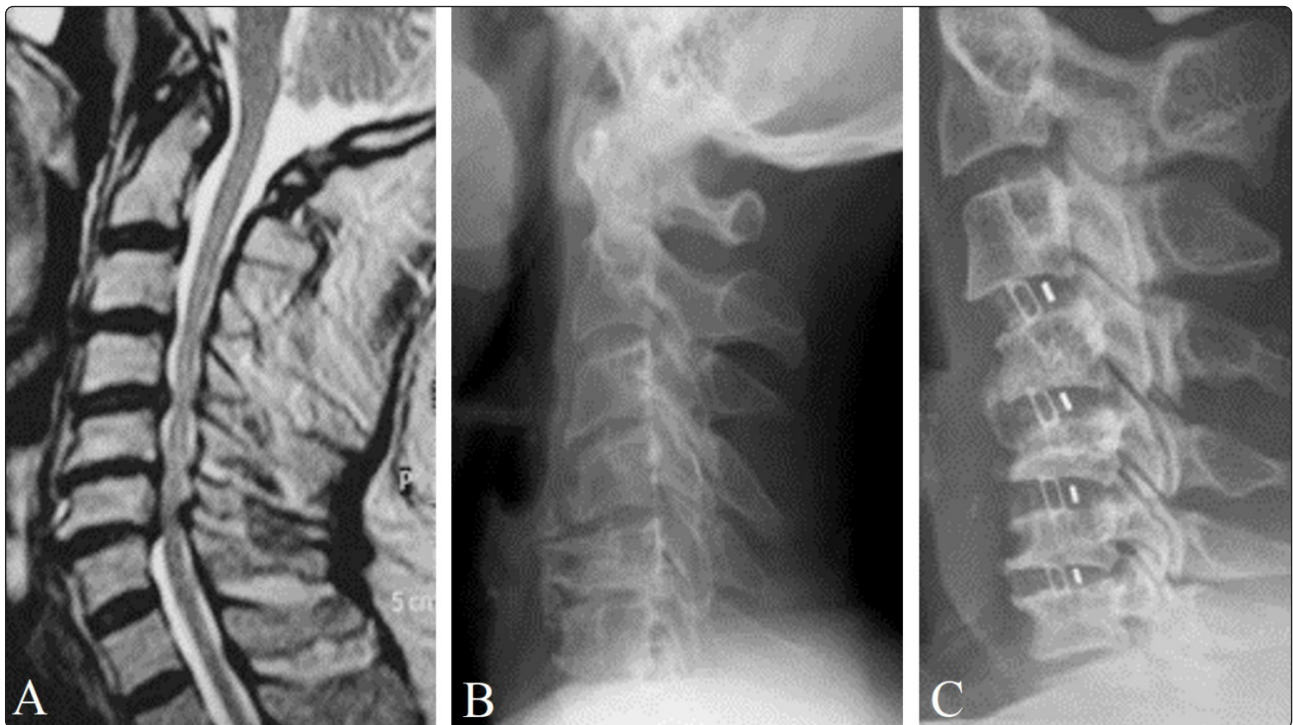


**Figure 1.** Box-and-whisker plot showing the cervical curve at different time points of follow-up in both groups.

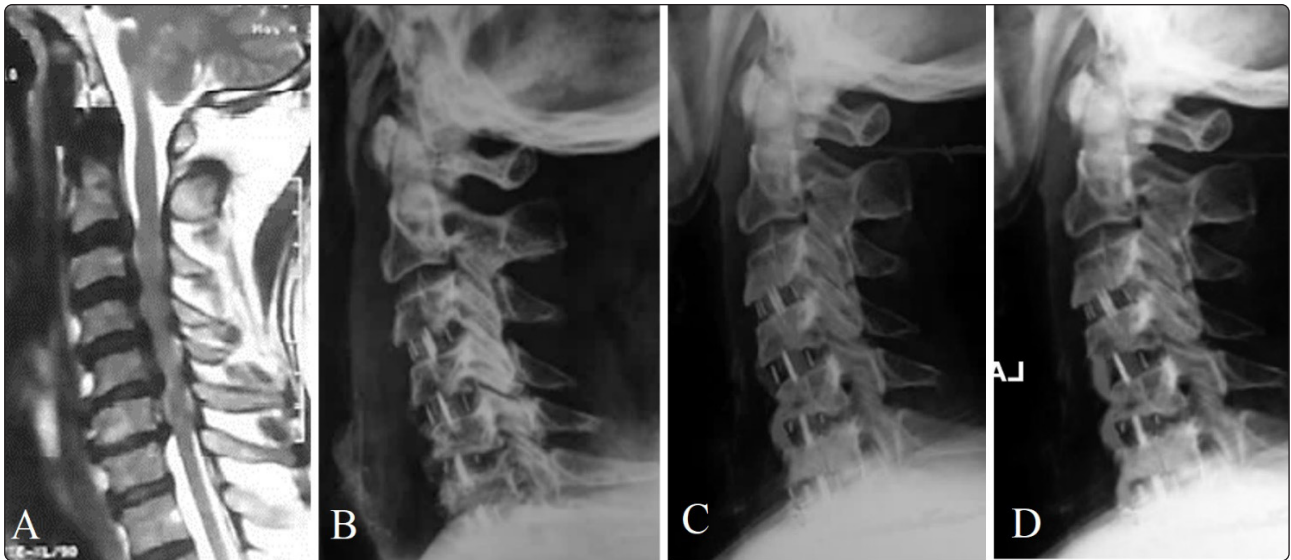




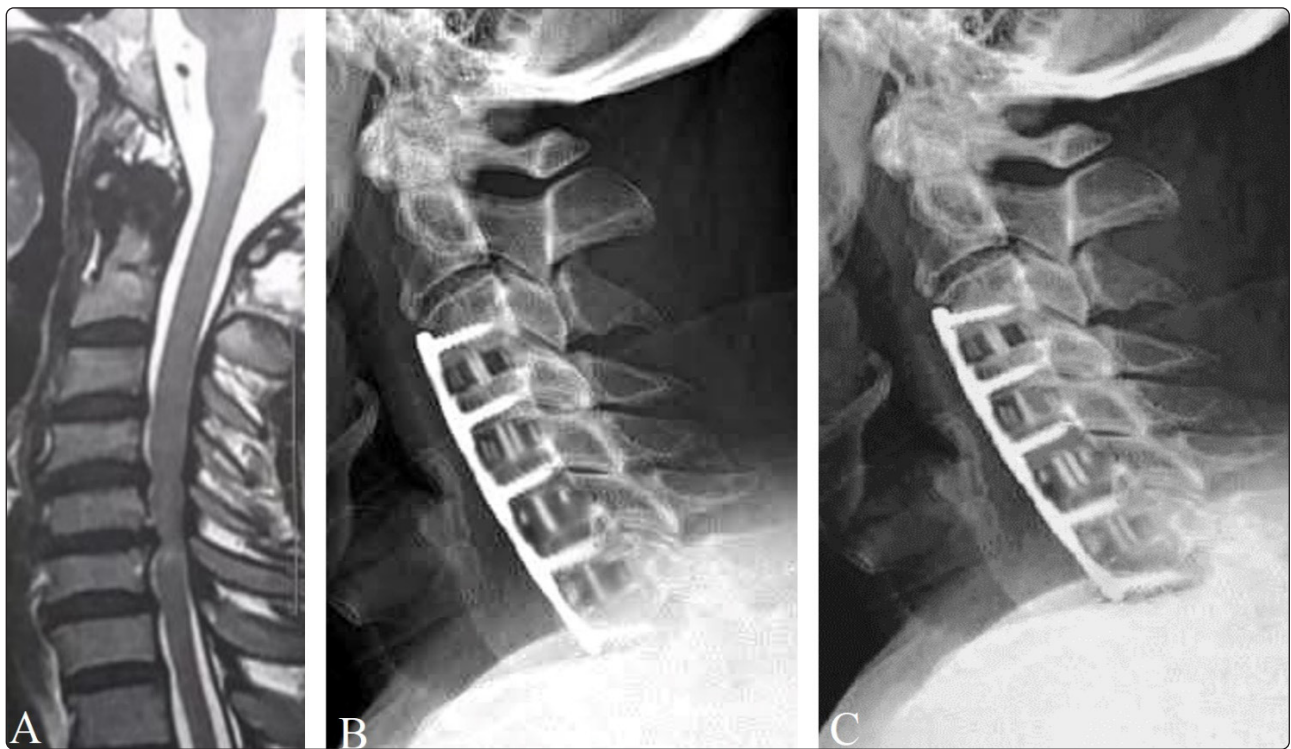
**Figure 2.** Box-and-whisker plot showing VAS scores of neck pain at different time points of follow-up in both groups.



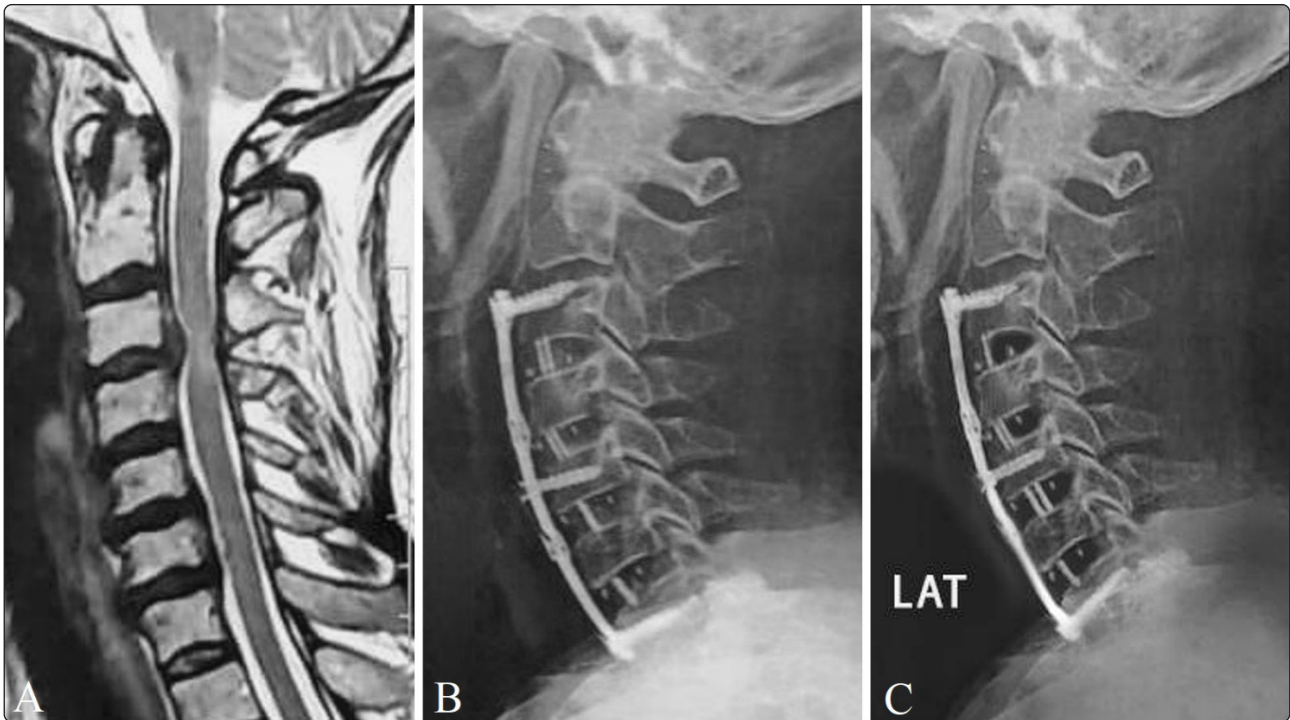
**Figure 3.** A 64-year-old male patient with cervical DDD: (A) preoperative T2 sagittal MRI; (B) preoperative lateral radiograph showing multispandylotic disc disease; (C) a 5-year follow-up radiograph showing a 4-level ACDF with bone fusion (Group 1).



**Figure 4.** A 65-year-old patient. (A) T2 sagittal MRI showing multilevel DDD. Serial follow-up radiographs (B) at 1 year, (C) at 3 years, and (D) at 5 years showing four-level stand-alone ACDF with bone fusion (Group 1).



**Figure 5.** A 40-year-old lady with multilevel cervical DDD: (A) preoperative T2 sagittal MRI; (B) lateral plain radiograph at one-year follow-up showing four-level ACDF with anterior plate; (C) lateral plain radiograph at four-year follow-up showing four-level ACDF with an anterior plate. Both showed good bone fusion (Group 2).



**Figure 6.** A 55-year-old lady with multilevel cervical DDD: (A) preoperative T2 sagittal MRI; (B) lateral plain radiograph at one-year follow-up showing four-level ACDF with anterior plate; (C) lateral plain radiograph at one-year follow-up showing five-level ACDF with anterior plate, both showing good cervical curve and bone fusion (Group 2).

There was a significant difference regarding the incidence of dysphagia. Ten patients (43.5%) developed postoperative dysphagia in Group 2 compared to none in Group 1. It was reported in all ten patients at 3 to 6 weeks after surgery; nine patients responded to conservative therapy. In one case, the patient underwent reoperation to remove the cervical plate three months after surgery and injection of retropharyngeal steroids to decrease swelling and the inflammatory reaction. In Group 1, one patient had cage dislodgement and required a bigger-sized insertion two months after surgery. One patient in each group had a surgical site infection; only one of them (Group 1) required reoperation to drain an abscess three weeks after surgery. Patient satisfaction was categorized into excellent, good, fair and poor. This assessment showed no significant difference between the two groups, although satisfaction was higher in Group 1 (Table 3).

## DISCUSSION

In this multicenter retrospective study, we compared long-term outcomes among patients who underwent ACDF either with cages only or with cages and anterior plating. Apart from patient satisfaction and postoperative dysphagia, no difference could be noticed between the two groups. Regarding our primary outcome (NDI), we found no difference between the two groups when compared at different follow-up intervals. However, our results demonstrated that patients in the two groups had improved NDI over time throughout follow-up intervals when compared to preoperative NDI in either group. This indicates that both techniques have effectively improved NDI to a similar degree. Moreover, in their retrospective analysis, Zhang et al. have reported the same finding when both techniques were compared for two-level noncontinuous cervical



discectomy.<sup>18</sup> Fusion rate showed no significant difference between the two groups at different time intervals of follow-up (1 year, 2 years, and last follow-up). The fusion rate in Group 1 at one year was 83.3% and 100% at five years, while in Group 2, it was 78.3% and 100% at both times. Zhang et al.<sup>18</sup> also reported fusion rate as 91.3% in the no-plate group compared to 95.2% in the plate group with no significant difference between the two groups at three-month follow-up and solid fusion for all patients at the final follow-up. Elsayed and Sakr<sup>5</sup> have also reported similar findings. Similarly, Cabraja et al.<sup>3</sup> found that the fusion rate when using PEEK cages alone was 88.1%. It has been considered beneficial to implant anterior plates in multilevel ACDF for improving fusion rate<sup>11</sup>; however, many of the recent reports<sup>18</sup>, in addition to our study, demonstrated no superiority of anterior plating to cages only without plating for the fusion rate.

We found no significant difference in the cervical curve between the two groups at different time points of follow-up. However, the intragroup analysis showed significant improvement of the cervical curve from the first postoperative day till the final follow-up in the two groups compared to the preoperative values. In their study, Zhang et al.<sup>18</sup> have described similar findings, highlighting that both techniques have a similar successful role in improving cervical curves.

We found no significant difference in VAS scores for pain between the two groups at different follow-up time points. However, the intragroup analysis showed a significant reduction in VAS scores in the two groups throughout the follow-up period when compared to preoperative VAS. Similar findings have been reported by Elsayed and Sakr<sup>5</sup>, as they reported a significant postoperative reduction in VAS scores for pain in each group compared to preoperative VAS; no significant difference was observed between both groups when compared to each other.

Operative time, intraoperative blood loss, and the need for reoperation did not differ significantly

between the two groups. In their study, Zhang et al.<sup>18</sup> have found a significantly reduced operative time in the no-plate group compared to the plate group.

We found a significant difference between the two groups regarding the incidence of postoperative dysphagia, 43.5% (10/23 patients) in Group 2 versus no patients in Group 1. Moreover, Zhang et al.<sup>18</sup> have found a significant difference between both groups with a higher incidence in the plate group. However, in their study, Zhang et al.<sup>18</sup> found an incidence of early postoperative dysphagia among patients in the no-plate group (3/23 at one month postoperatively), which have improved during the follow-up period. Dysphagia has been found to be the most common complication after ACDF.<sup>12</sup> It mostly disappears within three months postoperatively; however, up to 35.1% of these patients will continue to complain of dysphagia.<sup>8</sup> Despite being of unknown mechanism, dysphagia results from irritation of the esophagus by the anterior plate.<sup>13</sup> Despite the higher incidence of dysphagia in Group 2, we found a nonsignificant difference between both groups regarding patient satisfaction. Also, Elsayed and Sakr<sup>5</sup> have reported the same. This can be explained by the fact that patient satisfaction has multiple domains. Among our patients, two patients had postoperative surgical site infection (one in each group); both underwent proper treatment with proper antibiotics and improved over the following two weeks.

This study has the known limitations of any retrospective study, such as the relatively small number of enrolled patients. Moreover, patients' allocation was according to the surgeon's preference which weakens the results of this study. Despite these limitations and considering the long-term follow-up of our study, this study provides evidence of equal effectiveness of using four-level stand-alone PEEK cages ACDF compared to cages with anterior plating, with stand-alone PEEK cages being superior regarding postoperative dysphagia.

## CONCLUSION

Four-level ACDF with stand-alone PEEK cage is equally effective as ACDF with anterior plating in patients treated for four-level cervical DDD with less incidence of dysphagia.

## REFERENCES

1. Anderson DG, Albert TJ: Bone grafting, implants, and plating options for anterior cervical fusions. *Orthop Clin North Am* 33:317–328, 2002
2. Bridwell KH, Lenke LG, McEnery KW, Baldus C, Blanke K: Anterior fresh frozen structural allografts in the thoracic and lumbar spine. Do they work if combined with posterior fusion and instrumentation in adult patients with kyphosis or anterior column defects? *Spine* 1995;20:1410–1418
3. Cabraja M, Oezdemir S, Koeppen D, Kroppenstedt S: Anterior cervical discectomy and fusion: comparison of titanium and polyetheretherketone cages. *BMC Musculoskeletal Disorders* 13:172, 2012
4. Cloward RB: The anterior approach for removal of ruptured cervical disks. *J Neurosurg* 15:602–17, 1958
5. Elsayed A, Sakr S: Fixation of multiple level anterior cervical disc using cages versus cages and plating. *Egypt J Neurol Psychiatry Neurosurg* 55:12, 2019
6. Epstein NE: High posterior cervical fusion rates with iliac autograft and Nanoss/bone marrow aspirate. *Surg Neurol Int* 8:152, 2017
7. Jacobs W, Willems PC, Kruyt M, van Limbeek J, Anderson GP, Pavlov P, et al: Systematic review of anterior interbody fusion techniques for single- and double-level cervical degenerative disc disease. *Spine* 36:E950–960, 2011
8. Lee MJ, Bazaz R, Furey CG, Yoo J: Influence of anterior cervical plate design on Dysphagia: a 2-year prospective longitudinal follow-up study. *J Spinal Disord Tech* 18:406–409, 2005
9. Li Z, Wang H, Li L, Tang J, Ren D, Hou S: A new zero-profile, stand-alone Fidji cervical cage for the treatment of the single and multilevel cervical degenerative disc disease. *Journal of Clinical Neuroscience* 41:115–122, 2017
10. Park DK, Rhee JM, Kim SS, Enyo Y, Yoshiok K: Do CT scans overestimate the fusion rate after anterior cervical discectomy and fusion? *J Spinal Disorder Tech* 28(2):41–46, 2015
11. Resnick DK, Trost GR: Use of ventral plates for cervical arthrodesis. *Neurosurg* 60:S112–S117, 2007
12. Riley LH, Skolasky RL, Albert TJ, Vaccaro AR, Heller JG: Dysphagia after anterior cervical decompression and fusion: prevalence and risk factors from a longitudinal cohort study. *Spine* 30:2564–2569, 2005
13. Scholz M, Schnake KJ, Pingel A, Hoffmann R, Kandziora F: A new zero-profile implant for stand-alone anterior cervical interbody fusion. *Clin Orthop Relat Res* 469:666–673, 2011
14. Song KJ, Taghavi CE, Lee KB, Song JH, Eun HP: The efficacy of plate construct augmentation versus cage alone in anterior cervical fusion. *Spine* 34:2886–2892, 2009
15. Tong MJ, Xiang GH, He ZL, Chen DH, Tang Q, Xu HZ, et al: Zero-profile spacer versus cage-plate construct in anterior cervical discectomy and fusion for multilevel cervical spondylotic myelopathy: systematic review and meta-analysis. *World Neurosurg* 104:545–553, 2017

16. Vavruch L, Hedlung R, Javid D, Leszniewski W, Shalabi A: A prospective randomized comparison between the Cloward procedure and a carbon fiber cage in the cervical spine: a clinical and radiologic study. Spine 27:1694–1701, 2002
17. Xiao S, Liang Z, Wei W, Ning JP: Zero-profile anchored cage reduces risk of postoperative dysphagia compared with cage with plate fixation after anterior cervical discectomy and fusion. Eur Spine J 26:975–984, 2017
18. Zhang Z, Li Y, Jiang W: A comparison of zero-profile anchored spacer (ROI-C) and plate fixation in 2-level noncontiguous anterior cervical discectomy and fusion- a retrospective study. BMC Musculoskelet Disord 19:119, 2018

## الملخص العربي

### النتائج طويلة المدى لإيثاق الفقرات العنقية ذات الأربع مستويات بواسطة الاقفاص الكربونية مقابل اضافة شريحه اماميه: دراسه مرجعيه مقارنه متعددة المراكز

**البيانات الخلفية:** يعتبر التثبيت الامامي للفقرات العنقية الاختيار المثالي لامراض الانزلاق التي الغضروفي العنقي عند فشل العلاج التحفظي. كما ان التثبيت الامامي بواسطة الشرائح العنقيه يسمح بمزيد من الثبات وتحسين النتائج المرجوة وتقليل حدوث الالتحام الخاطئ للفقرات العنقية التي ق تسبب اعراضا خطيرة مثل صعوبة البلع .

التثبيت بواسطة الاقفاص العنقيه فقط يمكنه تجنب مثل هذه المضاعفات ولكن مع تعدد مستويات الانزلاق اصبح استخدامه موضعاً للجدل

**الغرض:** يهدف الي تقييم النتائج علي المدى البعيد اكلينيكيًا وعن طريق الفحص الراديولوجي بالاشعه لكلا الطريقتين (التثبيت بالاقفاص عنقية وحدها\_مقابل التثبيت بالاقفاص العنقيه بالاضافه الي الشرائح الاماميه)

**تصميم الدراسة:** دراسه أترابيه مرجعيه مقارنه متعددة المراكز

**المرضي والطرق:** شمل هذا البحث دراسة مرجعية متعددة المراكز ل 47 مريضا بالغا مصابون بانزلاق غضروفي عنقي متعدد خضعوا لجراحات تثبيت الفقرات العنقية الاماميه بواسطة اقفاص عنقيه فقط(24مريض)او اقفاص عنقية وشرائح امامية في الفترة ما بين يوليو 2012 ومايو 2016 وخضعوا للمتابعة لمدة خمس سنوات. النتائج الاوليه شملت تقييم مؤشر العجز العنقي ( NDI) للمتابعة الاخيرة. اما النتائج الثانوية فشملت مدة الجراحه كميّة الدم المفقود والمنقول ,معدل الالتحام,, والانحناء (القعس)العنقي ,, ومؤشر العجز بالرقبة NDI,, ونسبة الالم علي مقياس VAS SCORE,, رضا المريض والحاجه الي اعاده الجراحة وعسر البلع بالاضافه الي المضاعفات الاخري.

**النتائج:** لم تكن الخصائص الاساسيه مختلفة بين المجموعتين. فلا يوجد فرق بين كلا المجموعتين في درجات مؤشر الاعتلال العنقي NDI او الانحناء العنقي او درجة الاحساس بالالم علي مقياس VAS, في نقا زمنية مختلفه من المتابعة ومع ذلك اظهرت النتائج داخل المجموعة تحسنا كبيرا عند مقارنتها بما كان قبل الجراحة. كما ان معدل الالتحام والجودة والمضاعفات والحاجه الي اعاده الجراحه ورضا المرضي لم يكونوا مختلفين بشكل كبير في كلا المجموعتين.

**الخلاصة:** التثبيت بواسطة الاقفاص العنقيه فقط مساوي في الفاعلية للتثبيت بواسطة الاقفاص العنقيه والشرائح الاماميه في حالات الانزلاق الغضروفي العنقي المتعدد بل له نتائج افضل فيما يتعلق بصعوبة البلع ما بعد الجراحة.