

Lumbopelvic Fixation in Unstable Traumatic Spinopelvic Sacral Fractures: Clinical and Radiological Outcome

Mohammed Alaswad, MD., Hesham Habba, MD., Hassan Al-Shatoury, MD., Sherif H Ali, MD., Ali Abou-Madawi, MD.

Neurosurgical Department, Faculty of Medicine, Suez Canal University Hospital, Ismailia, Egypt.

ABSTRACT

Background Data: Although most sacral fractures can be treated conservatively, several surgical options are available for highly unstable fractures. Surgery aims to provide sacral realignment, fixation, and maybe neural decompression with subsequent pain relief and early mobilization. Surgical options are variable depending on the type of fractures and surgeon's experience. Spinopelvic fixation is one of the famous surgical procedures.

Purpose: To evaluate the safety and efficacy of lumbopelvic fixation for the treatment of unstable traumatic spinopelvic sacral fractures.

Study Design: Prospective cohort study.

Patients and Methods: All patients with unstable spinopelvic sacral fractures excluding those with other types of sacral fractures were recruited for this study. All patients were submitted to lumbopelvic fixation. Patients were evaluated clinically and radiologically, including full lumbar and pelvis X-Ray and 3D MSCT scan at the pre- and postoperative period. Clinical parameters included a full neurological examination, VAS, ODI, and modified Rankin scale.

Results: A total of 15 patients including 7 males and 8 females with mean age of 28 ± 8.11 years were recruited for this study. All patients were suffering from unstable traumatic spinopelvic type C sacral fractures according to AO Spine sacral fractures classification system. Four patients suffered from type C0, 2 from C1, 4 from C2, and 5 from C3. Neural insults were reported in 13 patients. The mean follow-up period was 19.2 ± 8.6 (range, 6–36) months. The mean preoperative VAS improved from 8.13 ± 1.25 to 2.6 ± 1.01 postoperatively, while the mean preoperative ODI improved from 88.53 ± 2.24 to 16.8 ± 3.16 postoperatively. According to the modified Rankin scale for functional recovery, 14 (93.3%) of the patients were categorized as excellent and good, while only one patient (6.6%) was categorized as fair outcome. Complete fractures' healing was reported in all patients and none required any revision procedure. Deformity correction was incomplete in 40% without clinical effects on patients. Surgical site infection was reported in 3 patients and one of them necessitated debridement.

Address correspondence and reprint requests: Hesham Habba, M.D.

Neurosurgical Department, Faculty of Medicine, Suez Canal University Hospital, Ismailia, Egypt.

E-mail: heshamhabba@yahoo.com

Submitted: December 21st, 2019.

Accepted: March 1st, 2020.

Published: April 2020.

The article does not contain information about medical device(s)/drug(s).

No funds were received in support of this work.

The authors report no conflict of interest.

Conclusion: Lumbopelvic fixation is a safe and effective procedure in the treatment of unstable traumatic spinopelvic sacral fractures. (2019ESJ196)

Keywords: Lumbopelvic fixation; Spinopelvic fractures; Sacral fracture.

INTRODUCTION

The sacrum is the mechanical nucleus of the axial skeleton serving as the base for the spinal column. Despite its mechanical importance, its transitional location between the spine and the pelvis has resulted in its being relatively overlooked by spine surgeons.¹

The lumbosacral neurologic function is protected by the sacrum and it maintains the spinal column and pelvic alignment. Thus, injuries to the sacrum may result in deformity, chronic pain, and loss of lower extremity function, bladder, bowel, and sexual function.² The surgical management for sacral fractures is challenging. Although they are rare injuries, they usually present with a wide variety of injury and fracture patterns. Sacral fractures often occur with pelvic and lower extremity fractures with or without concomitant neurologic dysfunction.² Sacral fracture with lumbopelvic dissociation usually happens after high-energy trauma. The most common mechanism is a jump or falls from height.³

Due to the great variation in patterns of sacral fractures and associated fractures as well as neurological injuries, many classification systems have been proposed starting with Denis system,⁴ Roy-Camille system,⁵ and finally the AO Spine sacral fractures classification system introduced by the AO Spine.⁶ The surgical options for treatment of sacral fractures are also variables and range from the percutaneous techniques to the open spinopelvic fixation procedure. Unstable sacral fractures are considered to be extremely devastating health problem that carry a great socioeconomic burden to either the patients, society, or health care providers. Spinopelvic fixation is one of the most important surgical options in the surgical management of these health problems.

This study aims to assess the safety and efficacy of the lumbopelvic fixation in the surgical management of unstable traumatic sacral fractures.

PATIENTS AND METHODS

Fifteen patients were prospectively recruited for this cohort study. All patients underwent the operation at Neurosurgery Department, Suez Canal University Hospital, through the period from 2016 to 2019 using the lumbopelvic fixation technique. All patients with unstable spinopelvic sacral fractures according to the AO Spine sacral fractures classification system excluding other types of sacral fractures were recruited for this study. Patients with other types of sacral fractures, metabolic bone diseases, and coagulopathy were excluded from our study.

After stabilization of the general conditions of the patients, all patients were submitted to general and neurological evaluation. Clinical parameters included a full neurological examination, Visual Analog Scale (VAS) of back pain, and the Oswestry Disability Index (ODI). VAS was determined on a graphic chart between 0 (no pain) and 10 (maximum pain intensity). Neurological recovery and function were assessed using the Gibbons classification⁷ of cauda equina impairment with its 4 subtypes: Type 1: none; Type 2: paresthesia only; Type 3: lower limb motor deficit; Type 4: bowel/bladder dysfunction.

Patients were submitted to radiographic evaluations including; full lumbosacral and pelvis plain radiographs anteroposterior and lateral views and MS 3D CT-scan of the lumbosacral spine and pelvis.

Types of fractures were categorized according to AO Spine sacral fractures classifications system. Immediately postoperative patients were submitted to full plain radiographs and MS 3D TC-scan of the lumbar spine and pelvis. This was repeated

at 6 months intervals after surgery to assess the integrity of the spinopelvic construct and to assess the healing of fracture lines.

Surgical Technique

All the patients underwent operation under general anesthesia in the prone position under elective conditions after stabilization of the patient's general condition. Intraoperative fluoroscopy guidance was used throughout the whole procedure. All our patients were systematically submitted for the Galveston technique which was established by Allen and Ferguson.⁸ Through a posterior midline approach, a subperiosteal muscle dissection was continued to expose L5 lamina and bilateral L5 screw entries. L5 screws were applied under image guidance before iliac screws were applied.

We continued with subperiosteal dissection to expose the posterior superior iliac spine (PSIS). Once the PSIS was identified, we used a Leksell rongeur to make a small recess approximately 1.5 cm cephalad and medial to it to accommodate the head of the iliac screw. This was done to avoid subcutaneous prominence of the screw head from the ilium. Using the free-hand technique, iliac screws' purchase on the ilium was established. Two gear-shift pedicle probes were angled so that their shafts were parallel to the L5 lamina with the tip of the probe pointing to the notch created in the ilium. The shafts of the two probes should intersect each other over the L5 spinous process to confirm that they were still parallel to the lamina. The direction of each probe after these steps were completed was the trajectory that each iliac screw should take during placement. This is approximately the trajectory from the PSIS to the anterior inferior iliac spine. Screw length is identified based on preoperative imaging and intraoperative probing. The screw penetrates above the dense cortical bone which surrounds the superior aspect sciatic notch. Additionally, if they follow the optimum direction, the trajectory of the probe will parallel the L5-S1 facet joint. Each iliac screw was applied so that there was no substantial screw head prominence. Contoured rods were tapped directly on all screws; or, instead, connectors were used to connect the

iliac screw to the contoured rods. Meticulous wound hemostasis and wound irrigation with betadine solution were performed, and a closed drain system was inserted.⁹⁻¹¹ Perioperative third-generation cephalosporins were used for 5 days. Patients were discharged from the hospital when the drain was removed and the wound was in good condition.

Postoperatively, patients were scheduled for routine outpatients' visits after 6 weeks, then at 3-month intervals where both back pain VAS and Oswestry Disability Index (ODI) were assessed at each visit. Full plain radiographs were performed at each visit and, in case of any further queries regarding healing, further 3D MSCT scan was requested. The endpoint of fracture union was defined by the disappearance of any visible fracture line in the sacral cortices on radiographs.

Statistical Analysis

Statistical analysis will be conducted using Statistical Package for Social Sciences (SPSS) version 20.0. The Kolmogorov-Smirnov, Shapiro, and D'Agostino tests were utilized to verify the normality of distribution of variables; the Mann-Whitney test was employed to compare the two groups for abnormally distributed quantitative variables. Pearson's coefficient was used to correlate between two normally distributed quantitative variables. Significance of the obtained results was judged at the 5% level. All data are expressed as mean±SD.

RESULTS

A total of 15 patients were prospectively recruited for this study. Seven (47%) patients were males and 8 (53%) were females with mean age 28±8.11 (range, 18–45) years. The reported causes of trauma were falling from heights in 10 (67%) including 5 suicidal attempts and road traffic accidents in 5 (33%) patients. (Table 1)

According to AO Spine sacral fractures classification system, all reported patients were type C fractures distributed as follows: C0, 4 cases; C1, 2 cases;

C2, 4 cases; C3, 5 cases. The reported associated injuries were diverse and included 2 spinal injuries including a traumatic L5/S1 spondylolisthesis and LV2 burst vertebral fracture. Other associated injuries included 5 patients with retroperitoneal hematoma, 6 with genitourinary injuries, and 4 with lower limb orthopedic fractures including 4 calcaneal and one femur fractures. Neurological assessment of patients showed that 2 patients were neurologically intact, and 9 (60%) patients suffered from urine retention, 4 from weak dorsiflexion, 5 from weak plantarflexion, 11 from saddle area anesthesia/hypesthesia, and 13 from lower limb sensory loss. (Table 2)

All patients underwent lumbopelvic fixation using iliac screws in 10 patients (Figure 1,2) and S2 alar iliac screws in 5 patients. The lumbar anchoring points were L5 transpedicular screws in all cases. S1 pedicle screws were used in all 5 cases which were managed by S2 alar iliac screw as a distal anchoring point and in one case of associated traumatic pars fracture of L5-S1. One case of associated LV2 fracture was managed using transpedicular short segment screws fixation of LV1-LV3. (Figure 3) (Table 1) There was no reported postoperative neurological deterioration in any of our patients. The mean operative time was 147.3 ± 30.6 (range, 120–200) minutes, the mean operative blood loss 643 ± 197 (range, 500–1000) ml, the mean hospital stays 12.8 ± 3.8 (range, 7–19) days, and the mean follow-up period 19.2 ± 8.6 (range, 6–36) months. The mean preoperative VAS improved from 8.13 ± 12.5 (range, 6–10) to 2.6 ± 10.1 (range, 1–5) postoperatively. The mean preoperative ODI improved from 88.53 ± 8.2 (range, 86–92) to 16.8 ± 7.6 (range, 12–22) postoperatively. According to the Gibbons classification of cauda equina

impairment, the mean preoperative impairment type was 3.4 ± 1.01 (range, 1–4). After a 6-month follow-up, the mean impairment type improved to 2.2 ± 0.90 (rang, 1–4), while, after a 12-month follow-up, 13 out of 15 patients showed mean impairment improvement to 1.6 ± 1.2 (range, 1–4). Ten patients out of 15 underwent surgical decompression during the procedures. The preoperative mean impairment of the decompression group improved from 4 ± 0 (all patients underwent decompression were of type 4) to 2.5 ± 0.80 and 2.1 ± 1.1 at 6- and 12-month follow-up, respectively. In the other 5 patients, the mean impairment improved from 2.2 ± 0.90 to 1.6 ± 0.8 and 0.6 ± 0.48 at 6 and 12 months, respectively. (Table 3)

The correlation between the neurological outcome and the timing of surgery was not statistically significant at 6-month ($r = 0.397$, $p = 0.143$) and at 12-month follow-up ($r = 0.497$, $p = 0.059$). Moreover, the correlation between the neurological outcome and surgical decompression was statistically insignificant at 6-month and at 12-month follow-up (p -value was 0.129 and 0.679, respectively).

Reported complications included the following: superficial surgical site infection in 3 (20 %), 2 of them treated with antibiotics and frequent dressings, while the other one treated with wound debridement followed by insertion of vacuum drain for 14 days. One patient underwent revision surgery for loosened cross-link, while the patient was still in the hospital. In this patient, we could not reduce the traumatic sacral kyphosis, and, meanwhile, he did not suffer from sphincter affection or significant back pain postoperatively. DVT was reported in one patient and managed well with anticoagulation therapy.

Table 1. Demography and surgical technique.

No.	Age/years	Sex	Trauma	Time to surgery/days	Surgical procedure	Decompression
1	18	M	Fall	7	L5-S1-S2 alar iliac screws	Yes
2	23	F	Fall	10	L5-Iliac fixation with side connector	No
3	26	M	RTA	4	L5-Iliac fixation, T12-L1-L2 fixation	Yes
4	45	F	Fall	18	L5-iliac fixation without side connector	Yes
5	22	M	Fall	5	L5-S1-S2 alar iliac screws	Yes
6	40	F	RTA	7	L5-iliac fixation without side connector	No
7	26	F	Fall	12	L5-S2 alar iliac screws	No
8	29	M	RTA	5	L5-iliac fixation with side connector	Yes
9	19	M	Fall	8	L5-iliac fixation with side connector	No
10	30	F	Fall	9	L5-S1-S2 alar iliac screws	Yes
11	24	F	RTA	13	L5-iliac fixation without side connector	Yes
12	43	M	Fall	5	L5-S1-S2 alar iliac screws	Yes
13	21	F	RTA	14	L5-iliac fixation without side connector	Yes
14	25	F	Fall	11	L5-iliac fixation without side connector	No
15	23	M	FALL	12	L5-iliac fixation with side connector	Yes
Total	28±8.11	NA	NA	9.3±4.01	NA	NA

RTA: road traffic accident; M: male; F: female.

Table 2. Fracture type and clinical status.

Cases	AO Spine type	Saddle area	Sphincter affection	Motor weakness/sensory loss	Associated injuries
1	C3	Anesthesia	Yes	Right weak dorsiflexion, right L5 hypesthesia	L5/S1 traumatic spondylolisthesis, bladder injury
2	C0	Intact	No	Intact	Bilateral calcaneus fracture
3	C3	Hypesthesia	Yes	Right weak dorsiflexion, right L5 hypesthesia	Retroperitoneal hematoma
4	C2	Anesthesia	Yes	Bilateral weak dorsiflexion and plantarflexion, L5-S1 hypesthesia	Retroperitoneal hematoma
5	C3	Anesthesia	Yes	Bilateral weak dorsiflexion and plantarflexion, L5-S1 hypesthesia	Bilateral calcaneus fracture
6	C0	Intact	No	Intact	Retroperitoneal hematoma
7	C2	Intact	No	Left weak dorsiflexion, left L5 anesthesia	Bilateral calcaneus fracture, vaginal tear
8	C2	Hypesthesia	Yes	Right weak dorsiflexion, right L5 anesthesia	Abdominal collection, pneumothorax
9	C0	Intact	No	Left weak dorsiflexion, left L5 hypesthesia	Kidney injury, hemothorax
10	C3	Anesthesia	Yes	Bilateral weak dorsiflexion and plantarflexion, L5-and S1 anesthesia	Lt calcaneus fracture, abdominal collection
11	C3	Anesthesia	Yes	Right weak plantarflexion/ right S1 anesthesia	Bladder injury, pneumothorax
12	C3	Hypesthesia	Yes	Bilateral weak dorsiflexion and plantarflexion, L5-S1 hypoesthesia	Bladder injury
13	C1	Intact	No	Left weak dorsiflexion, left L5 hypesthesia	Vaginal tear, urethral injury
14	C1	Intact	No	Right weak plantarflexion/ right S1 hypesthesia	LV2 burst fracture, retroperitoneal hematoma
15	C2	Anesthesia	Yes	Bilateral weak dorsiflexion, L5 hypesthesia	Both bone Rt leg fracture

Table 3. Preoperative and postoperative outcome clinical parameters.

No.	VAS		ODI		Gibbons			Follow-up/mos
	Preop	Postop	Preop	Postop	Preop	6 mos postop	12 mos postop	
1	7	3	90	16	4	2	NA	6
2	8	2	86	18	1	1	NA	10
3	10	5	92	20	4	2	1	12
4	9	2	86	22	4	4	4	18
5	9	1	86	12	4	3	2	18
6	8	2	90	12	1	1	1	24
7	7	3	86	12	3	3	1	18
8	10	4	88	14	4	2	2	9
9	9	3	90	20	3	2	NA	12
10	6	3	88	18	4	2	2	24
11	7	2	86	16	4	4	4	20
12	9	3	88	16	4	2	2	36
13	6	3	88	16	4	2	2	26
14	8	2	92	20	3	1	1	20
15	9	1	92	20	4	2	2	36
Total	8.13±12.5	2.6±10.1	88.53±8.2	16.8±7.6	3.4±1.01	2.2±0.90	1.6±1.2	19.2±8.6

VAS: Visual Analog Scale; ODI: Oswestry Disability Index; Preop: preoperative; Postop: postoperative; Decomp: decompression; mos: months.

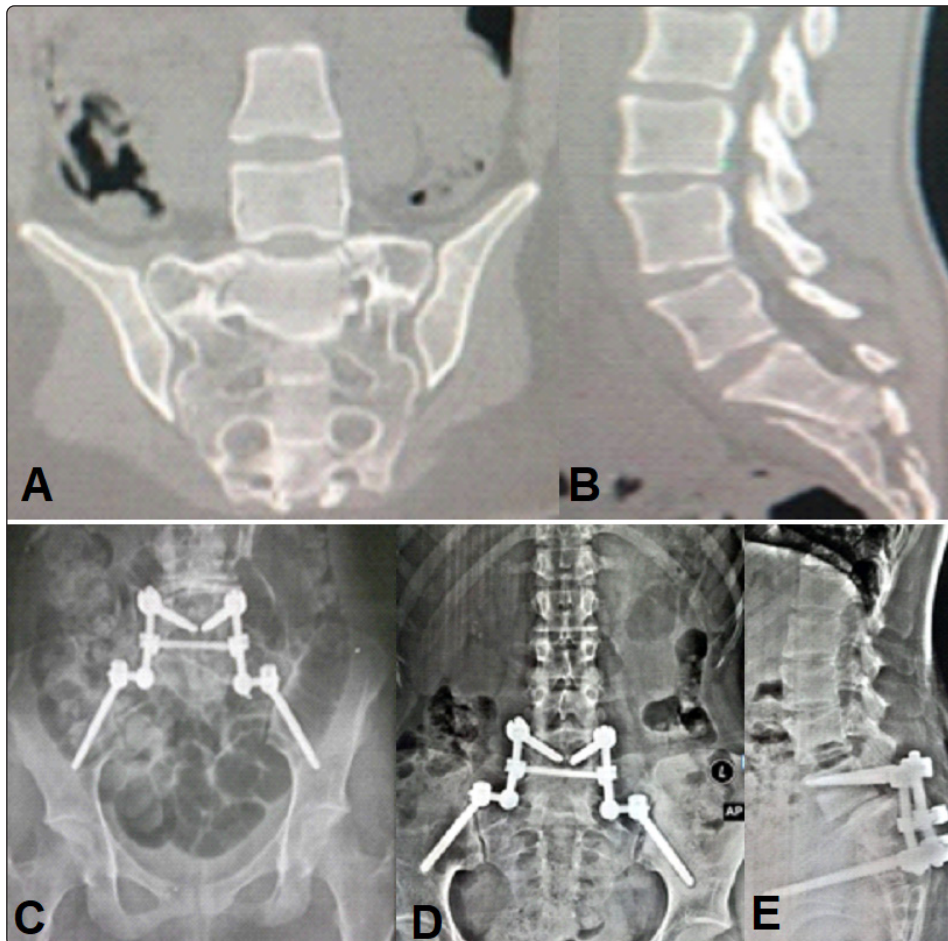


Figure 1. Images of (patient No. 9) 19 years old male patient presented after a fall from height with AO spine type C 3 sacral fracture, MSCT-Scan (A) Coronal and (B) sagittal images depicting a type-C3 sacral fracture, (C) 3 month postoperative AP view plain radiograph depicting lumbopelvic fixation, 12 months postoperative (D) AP view and (E) lateral radiographs showing stable construct with fracture healing.

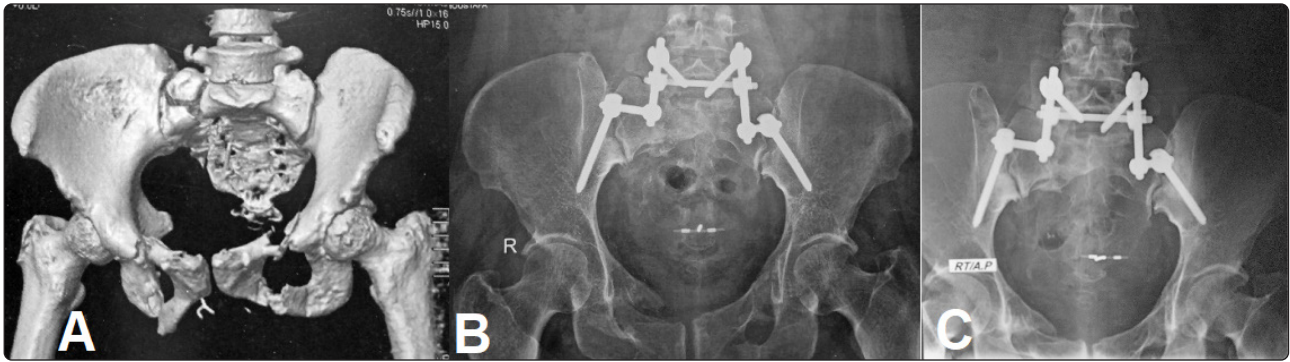


Figure 2. Images of (patient No. 4) 45 years old female patient presented after a fall from height with AO Spine type C 1 sacral fracture, (A) 3D CT-Scan depicting type C1 sacral fracture associated with bilateral pubic rami fractures, (B) 6 months and (C) 12 months postoperative AP view plain radiographs showing lumbopelvic fixation with stable construct with fracture healing.

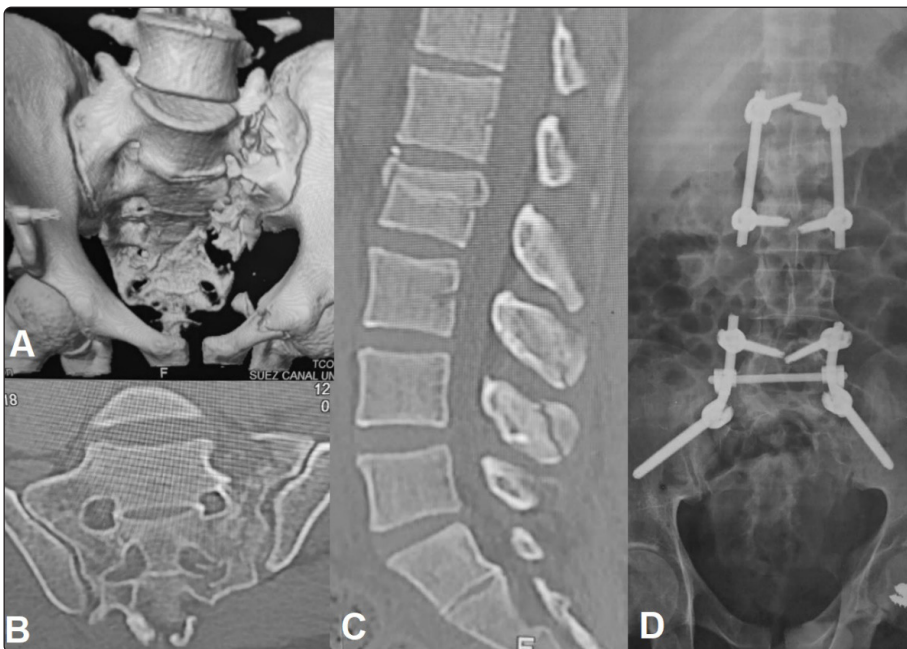


Figure 3. Images of (patient No. 14) 25 years old male patient presented after a fall from height with AO spine type C 1 sacral fracture, (A) 3D CT-Scan depicting type C1 sacral fracture associated with unilateral pubic ramus fracture and LV2 burst fracture, (B) coronal CT images depicting the sacral fracture, (C) sagittal CT-Scan depicting burst LV2 and LV3,4 spinous process fractures, (D) 12 months postoperative AP view plain radiograph depicting lumbopelvic fixation and short segment lumbar fixation with stable construct with sound fracture healing.

DISCUSSION

Sacral fractures are a challenging traumatic condition occurring in approximately 45% of pelvic injuries. The treatment options of sacral fractures are demanding and controversial surgical problems. The surgical option is not affected only by the extreme variations of the fracture patterns of

the sacrum itself but also by concomitant injuries of the pelvis and lumbar spine. Treatment of sacral fractures requires implicating a comprehensive understanding of neural decompression and skeletal reconstruction techniques to optimize both neurologic (neural decompression) and structural outcome (fracture stabilization and alignment).² Surgical treatment of sacral fractures should address simultaneously the problem of mechanical

instability and neurologic impairment. Pelvic ring interruption, nerve root compression, cauda equina syndrome, and, on some occasions, associated direct injury to the spinal column were also reported as associated injuries with sacral fractures.¹² Although most sacral fractures can be treated conservatively, several surgical options are available for the management of unstable sacral fractures. The main clinical aims of surgery are to allow early mobilization of the patients and pain relief. This could be achieved through surgical stabilization and/or neural decompressive procedures. Surgical treatment is often offered to patients with unstable sacral fracture patterns, concomitant pelvic ring injury, and/or neurologic dysfunction with radiographic evidence of compression.¹ Patients with a stable pelvis doing well clinically could be managed conservatively. Other surgical indications include nerve root compression, fractures with pseudoarthrosis, and extensive lumbosacral disruption.⁷

Relative indications for operations include multiple trauma cases to achieve early ambulation in order to aid in the process of rehabilitation. Besides obtaining fixation of the fracture, other aims include securing the lumbosacral equilibrium, promoting the clinical condition, and decreasing disability. Moreover, fixation of the sacral fractures provides stability which facilitates ambulation, preserves the sacral nerves and vessels, and relieves pelvic pain.^{13,14}

Unstable sacral fractures are usually associated with neural compromise. In this case, internal fixation is usually required to recover the pelvic strength and preserve the neural structure.¹⁵ Adequate reduction and internal fixation for an unstable sacral fracture might avoid neural compromise due to fibrosis.¹⁶ Cases with sacral fracture and neural compromise should undergo nerve exploration and decompression to remove the fracture fragments from nerve roots. Clinical and neurologic improvement are elevated to 80% postoperatively.¹⁷ This study reported 15 patients with unstable spinopelvic sacral fractures who underwent operation using the lumbopelvic fixation procedure.

Acceptable reduction has been achieved in most patients and fractures showed osteal healing within 3 to 6 months postoperatively with no postoperative displacement.

Before the 1960s, in situ fixation and prolonged bed rest with gypsum were the method of choice to achieve lumbosacral spine stability;¹⁰ however, these were correlated with a high rate of nonunion (up to 50%). With the advancement of surgical modalities such as the Harrington-Luque and Cotrel-Dubousset techniques in spine surgery, the spine fusion ratio increased. However, disadvantages were detected such as back deformity, neural structure damage, and implant failure. With the recent improvement of internal fixation technology, more implants were adopted to accomplish lumbosacral spine stability in sacral fractures, such as lumboiliac plates,⁵ transiliac plates,¹⁸ transiliac rods,¹⁹ and percutaneous iliosacral screws.²⁰ No agreement has been reached on the best technique for sacral fixation. The lumbopelvic internal fixation is one of the techniques that can accomplish lumbosacral fixation and spinal fusion and considerably increase the fusion ratio.²¹

Reported complications of lumbopelvic fixation are mainly surgical site infection and implant failure with overall surgical site infection rate 26–50%.²² Due to the delicate soft tissue in the sacrococcygeal region, the potentials of neural structure compromise the sacral fracture, sacral decompression technique might damage the blood supply of the nearby soft tissue, and the possibility of posteriorly protruding screw head, rod end, or red connectors is a major concern of the lumbopelvic fixation.²³

In a series with unstable first- and second-region fractures including 60 cases, Routt et al.²⁴ found that delays in the operation of 5 days or more were associated with weaker closed reduction ratios. Denis et al.⁴ found that delays of more than 14 days had poorer results in cases doing well clinically. In our study, regarding the time of surgery after trauma, the cases that underwent the operation in the first 7 days had a higher rate of infection, while the cases that underwent operation later on had

a much lower infection rate. This was attributed mainly to the presence of soft-tissue edema and stabilization of the general condition so they had better healing power. The Morel-Lavallée lesion is a soft-tissue injury reported with pelvic trauma in which the subcutaneous tissue is peeled away from the underlying fascia, resulting in a cavity filled with hematoma and seroma. A shearing force, for example, motor car accidents, has been incriminated to be the main cause. A study of 24 patients by Hak et al.²⁵ in 1997 reported that the commonest sites to be affected are lumbosacral and flank areas. Vanhegan et al.²⁶ after studying 204 lesions from 29 series revealed the frequency of the lumbosacral area to be 3.4%. These soft-tissue injuries varied in severity among patients and, whatever the severity, presence of hematoma and soft-tissue edema increase the risk of infection.²⁶ Moreover, the expanding hematoma in a closed internal degloving injury may further compromise the skin vascularity. In our series, we did not experience the classic degloving injury; however, in early cases, we experienced soft-tissue edema and muscular hematomas at the site of operation. In addition to this, the excessive use of electrocautery devitalizes the tissue more. As a result, antiedematous medications administration until the healing power of tissue improved, significantly reduce the postoperative infection rate.

Regarding neurological outcome after neural decompression in this series, patients suffering from sphincter and/or neurological injuries showed no difference in outcome whether the operation was done early or late after trauma. Therefore, we recommend decompression as a part of correcting the deformity rather than enhancing neurologic recovery. The management of neurological injuries associated with sacral fractures is still problematic. Some advocates²⁷ support decompression routinely, while others²⁸ do not recommend routine surgical decompression as they think that neurological injury is a direct injury including contusions and lacerations. However, the comparative studies in the literature regarding functional and

neurological recovery following sacral fractures are scarce.²⁹ Denis et al.⁴ observed that five patients who had neurological improvement after surgical decompression with another case had conducted delayed surgical decompression and showed poor outcomes. Therefore, they supported early surgical decompression. Schmidek et al.²⁷ supported the same results in their 11-patient series with transverse sacral fractures after surgical decompression. Kim et al.¹⁷ reported a group of 6 patients in which 5 patients neurologically improved. On the other hand, Sabastian and Wing²⁸ advised nonsurgical treatment for a group of 35 sacral fractures treated nonoperatively. This study, however, showed only one patient with a complete cauda equine syndrome who did not show significant neurological improvement. Phelan et al.³⁰ also recommend conservative treatment for these types of injuries. They followed up with only four patients who showed neurological recovery spontaneously. Nork et al.²⁰ reported neurological improvement in 7 patients who underwent percutaneous iliosacral fixation without surgical decompression and emphasized the importance of surgical fixation for neurological recovery. Elhabashy et al.³¹ reported similar results in their study upon 20 patients operated for sacral fracture without surgical decompression using the percutaneous iliosacral screws.

Some surgeons prefer to insert pedicle screws at L4 or L5 and S1 during iliolumbar fixation. As the plane of the sacrum screw is higher than that of the pedicle screw in this case, the fixed link must be bent into an S-shape so that it can fit adequately with the screws.¹⁶ In our study, we used mainly L5 pedicle screws, iliac screws, and S2 alar iliac screws for fixation. By using the S2 alar iliac screws, we avoid excessive dissection too laterally to reach the posterior superior iliac spine. Tian et al.³² recommended the use of long iliac screws with a trajectory toward the anterior inferior iliac spine just above the sciatic notch. This method created a center of rotation just anterior to the lumbosacral junction, protecting against the long lever arm force of flexion created by the

spine component.²¹ There are other techniques adopted to cross the sacral fractures that we did not use in this study and include iliosacral screws³¹ and transsacral plating.³³ To overcome this issue, we used one transversal cross-link to convert the bilateral lumbopelvic fixation into a more rigid structure. These cross-links, despite being not strong enough in mechanics compared to other cross fixation techniques, facilitate the procedure and reduce its morbidity. Furthermore, they restabilize the disrupted posterior pelvic ring in continuity through compression.

The number of anchor points needed in the lumbar and iliac area is still controversial.³⁴ Some authors²⁹ recommend a pair of pedicle screws in the L5 vertebra, providing adequate anchor points as long as there are no anterior pelvic ring injuries. On the other hand, the presence of anterior pelvic fractures and/or comminuted transverse fractures warrants the insertion of more screws. Furthermore, the current fusion procedures of sacral fractures are not motion preservation techniques that need further research studies in this field.²⁹

In our series, 3 patients developed surgical site infection which was mainly in the early cases and this was avoided in the later cases by reducing the usage of electrocautery (monopolar); instead, we used sharp technique in dissection using a scalpel, scissors, and bipolar for hemostasis. This decreased tissue necrosis and decreased exudates formation as a result of tissue degradation which resulted in a lower rate of postoperative infection or seroma formation. This observation was in agreement with Hak et al.²⁵ who reported that hematomas and soft-tissue edema in the operative site affect the safety of early operative intervention by increasing the risk of infection. The relationship between electrocautery and wound infection in different surgical specialties has been extensively studied, although it is scarce in neurosurgery practice. Sheikh et al.³⁵ performed 177 skin incisions for neurosurgical procedures using the microneedle electrocautery scalpel and the steel scalpel and reported only two cases of wound infection and

dehiscence in the electrocautery group. In terms of the electrocautery usage in breast surgery which is a fatty area that could be associated with seroma formation and infection, Kathaleen et al.³⁶ reported seromas in 16 wounds in the electrocautery patients compared to only 5 in the scalpel arm (38% and 13%, respectively; $P < 0.01$). Other results were reported in other studies^{37,38} observing that electrocautery did not significantly affect the rate of postoperative subcutaneous wound infection. As a routine, all our patients received regular anti-deep venous thrombosis (DVT) measures; however, one of our patients developed postoperative DVT and has been managed with short- and long-term anticoagulants. There is an agreement that all trauma patients are at an increased risk of DVT. This consensus reported that patients with an acute head or spinal cord injury have a 40% incidence of DVT and a greater than 1% incidence of fatal pulmonary embolism (PE).³⁹

This study is limited by a low number of patients and the short-term follow-up period for that reason the validity of correlation and multivariate analysis and statistical significance cannot be relied on. A multicenter prospective study with long-term follow-up is recommended.

CONCLUSION

Lumbopelvic fixation is a safe and effective method of treatment of traumatic unstable spinopelvic sacral fractures.

REFERENCES

1. Vaccaro AR, Kim DH, Brodke DS, Harris M, Chapman J, Schildhauer T, et al: Diagnosis and management of sacral spine fractures. *JBJS* 86(1):166–175, 2004
2. Mirzashahi B, Farzan M, Sadat M, Zarei M, Habibollahzade P: Surgical treatment of sacral fractures: a case series study. *J Orthop Spine Trauma* 1:e2061, 2015

3. He S, Zhang H, Zhao Q, He B, Guo H, Hao D: Posterior approach in treating sacral fracture combined with lumbopelvic dissociation. *Orthopedics* 37(11):e1027–e1032, 2014
4. Denis F, Davis S, Comfort T: Sacral fractures: an important problem. Retrospective analysis of 236 cases. *Clinical Orthopaedics and Related Research* 227:67–81, 1988
5. Roy-Camille R, Saillant G, Gagna G, Mazel C: Transverse fracture of the upper sacrum. Suicidal jumper's fracture. *Spine* 10(9):838–845, 1985
6. Bellabarba C, Schroeder GD, Kepler CK, Kurd MF, Kleweno CP, Firoozabadi R, et al: The AOSpine sacral fracture classification. *Global Spine Journal* 6 Suppl 1:s-0036-1582696-s-0036-1582696, 2016
7. Ayoub MA: Displaced spinopelvic dissociation with sacral cauda equina syndrome: outcome of surgical decompression with a preliminary management algorithm. *European Spine Journal* 21(9):1815–1825, 2012
8. Allen Jr B, Ferguson R: The Galveston technique of pelvic fixation with L-rod instrumentation of the spine. *Spine* 9(4):388–394, 1984
9. Emami A, Deviren V, Berven S, Smith JA, Hu SS, Bradford DS: Outcome and complications of long fusions to the sacrum in adult spine deformity: luque-galveston, combined iliac and sacral screws, and sacral fixation. *Spine* 27(7):776–786, 2002
10. Fountain S, Hamilton R, Jameson R: Transverse fractures of the sacrum. A report of six cases. *The Journal of Bone and Joint Surgery American volume* 59(4):486–489, 1977
11. Fridley J, Fahim D, Navarro J, Wolinsky J, Omeis I: Free-hand placement of iliac screws for spinopelvic fixation based on anatomical landmarks. *International Journal of Spine Surgery* 8, 2014
12. Robles LA, Plantillas E: An unusual transverse sacral fracture treated with early decompression: case report. *Journal of Neurosurgery: Spine* 5(6):546–549, 2006
13. Dalbayrak S, Yilmaz M, Kaner T, Gokdag M, Yilmaz T, Sasani M, et al: Lumbosacral stabilization using iliac wings: a new surgical technique. *Spine* 36(10):E673–E677, 2011
14. Keel MJB, Benneker LM, Siebenrock KA, Bastian JD: Less invasive lumbopelvic stabilization of posterior pelvic ring instability: technique and preliminary results. *Journal of Trauma and Acute Care Surgery* 71(3):E62–E70, 2011
15. Mouhsine E, Wettstein M, Schizas C, Borens O, Blanc C-H, Leyvraz P-F, et al: Modified triangular posterior osteosynthesis of unstable sacrum fracture. *European Spine Journal* 15(6):857–863, 2006
16. Vilela MD, Gelfenbeyn M, Bellabarba C: U-shaped sacral fracture and lumbosacral dislocation as a result of a shotgun injury: case report. *Neurosurgery* 64(1):E193–E194, 2009
17. Kim MY, Reidy DP, Nolan PC, Finkelstein JA: Transverse sacral fractures: case series and literature review. *Canadian Journal of Surgery* 44(5):359, 2001
18. Taguchi T, Kawai S, Kaneko K, Yugue D: Operative management of displaced fractures of the sacrum. *Journal of Orthopaedic Science* 4(5):347–352, 1999
19. Ebraheim NA, Savolaine ER, Shapiro P, Houston T, Jackson WT: Unilateral lumbosacral facet joint dislocation associated with vertical shear sacral fracture. *Journal of Orthopaedic Trauma* 5(4):498–503, 1991
20. Nork SE, Jones CB, Harding SP, Mirza SK, Routt Jr MC: Percutaneous stabilization of U-shaped sacral fractures using iliosacral screws: technique and early results. *Journal of Orthopaedic Trauma*. 15(4):238–246, 2001

21. Schildhauer TA, McCulloch P, Chapman JR, Mann FA: Anatomic and radiographic considerations for placement of transiliac screws in lumbopelvic fixations. *Clinical Spine Surgery* 15(3):199–205, 2002
22. Kellam J, McMurtry R, Paley D, Tile M: The unstable pelvic fracture. Operative treatment. *The Orthopedic Clinics of North America* 18(1):25–41, 1987
23. Bellabarba C, Schildhauer TA, Vaccaro AR, Chapman JR: Complications associated with surgical stabilization of high-grade sacral fracture dislocations with spino-pelvic instability. *Spine* 31(11S):S80–S88, 2006
24. Routt MC, Simonian PT, Swiontkowski MF: Stabilization of pelvic ring disruptions. *Orthopedic Clinics* 28(3):369–388, 1997
25. Hak DJ, Olson SA, Matta JM: Diagnosis and management of closed internal degloving injuries associated with pelvic and acetabular fractures: the Morel-Lavallee lesion. *Journal of Trauma and Acute Care Surgery* 42(6):1046–1051, 1997
26. Vanhegan IS, Dala-Ali B, Verhelst L, Mallucci P, Haddad FS: The Morel-Lavallée lesion as a rare differential diagnosis for recalcitrant bursitis of the knee: case report and literature review. *Case Reports in Orthopedics*, 2012
27. Schmidek HH, Smith DA, Kristiansen TK: Sacral fractures. *Neurosurgery* 15(5):735–746, 1984
28. Sabiston CP, Wing PC: Sacral fractures: classification and neurologic implications. *The Journal of Trauma* 26(12):1113–1115, 1986
29. Zelle BA, Gruen G, Hunt T, Speth S: Sacral fractures with neurological injury: is early decompression beneficial? *International Orthopaedics* 28(4):244–251, 2004
30. Phelan S, Jones D, Bishay M: Conservative management of transverse fractures of the sacrum with neurological features. A report of four cases. *The Journal of Bone and Joint Surgery British Volume* 73(6):969–971, 1991
31. Elhabashy AM, Issa AE, Abo Alfa A, Foad W, Khedr W: Efficacy and safety of minimally invasive percutaneous Ilio-Sacral fixation technique for sacral fractures in the initial twenty cases at department of neurosurgery in Alexandria university. *Egyptian Spine Journal* 33(1):14–25, 2020
32. Tian X, Li J, Sheng W, Qu D, Ouyang J, Xu D, et al: Morphometry of iliac anchorage for transiliac screws: a cadaver and CT study of the Eastern population. *Surgical and Radiologic Anatomy* 32(5):455–462, 2010
33. Hunt N, Jennings A, Smith M: Current management of U-shaped sacral fractures or spino-pelvic dissociation. *Injury* 33(2):123–126, 2002
34. Ebraheim NA, Biyani A, Salpietro B: Zone III fractures of the sacrum: a case report. *Spine* 21(20):2390–2396, 1996
35. Sheikh B: Safety and efficacy of electrocautery scalpel utilization for skin opening in neurosurgery. *British Journal of Neurosurgery* 18(3):268–272, 2004
36. Porter K, O'Connor S, Rimm E, Lopez M: Electrocautery as a factor in seroma formation following mastectomy. *The American Journal of Surgery* 176(1):8–11, 1998
37. Rongetti RL, e Castro PdTO, da Costa Vieira RA, Serrano SV, Mengatto MF, Fregnani JHTG: Surgical site infection: an observer-blind, randomized trial comparing electrocautery and conventional scalpel. *International Journal of Surgery* 12(7):681–687, 2014
38. Groot G, Chappell EW: Electrocautery used to create incisions does not increase wound infection rates. *The American Journal of Surgery* 167(6):601–603, 1994
39. Britt L, Zolfaghari D, Kennedy E, Pagel KJ, Minghini A: Incidence and prophylaxis of deep vein thrombosis in a high risk trauma population. *The American Journal of Surgery* 172(1):13–14, 1996

الملخص العربى

تثبيت الفقرات القطنية مع الحوض فى حالات كسور الفقرات العجزية الناتجة عن حوادث

البيانات الخلفية: على الرغم من إن معظم كسور الفقرات العجزية يمكن علاجها بشكل تحفظى إلا أنه تتوفر العديد من الخيارات الجراحية للكسور غير المستقرة و التى تهدف الى حدوث التحام مبكر و يساعد على حركة المريض المبكرة بالإضافة الى علاج الألم و تتكون خطة العلاج من إجراء تثبيت بواسطة قضبان و مسامير مع إزالة الضغط عن الحبل الشوكى.

الغرض: تقييم أمان و فاعلية تثبيت الفقرات القطنية مع الحوض فى حالات كسور الفقرات العجزية الناتجة عن حوادث.

تصميم الدراسة: دراسة استطلاعية.

المرضى والطرق: كل المرضى الذين يعانون من كسور الفقرات العجزية و أجريت لهم جراحة تثبيت الفقرات القطنية مع الحوض تم إجراء تقييم اكلينيكى لهم قبل و بعد الجراحة للقوة الحركية و القدرة على التحكم فى الاخراج و تقييم نسبة اللام و تقييم نسبة اللام ,

النتائج: تم إجراء تثبيت الفقرات القطنية مع الحوض فى 15 مريض , و حدثت الاصابة نتيجة سقوط فى 10 مريض ونتيجة حادث سير فى 5 حالات و اشتملت الدراسة على 7 حالة من الذكور و 8 حالة من الاناث و كان الكسر من النوع الثانى لتصنيف دنيس فى 5 حالات بينما كان من النوع الاول فى 5 حالات و النوع الثالث فى 5 حالات و تراوحت مدة المتابعة من 6 أشهر الى 36 شهر و أظهر متوسط المؤشر البصرى لقياس الألم تحسن ملحوظ من 8 قبل الجراحة الى 2.6 بعد الجراحة و قلت نسبة العجز من 89 قبل الجراحة الى 17 بعد الجراحة و كانت نسبة حدوث عدوى بالجرح 20% معظمهم فى الحالات الأولى و تحسنت فى الحالات التالية بعد اتخاذ احتياطات معينة. وكانت نسبة اللام 100% و على الرغم من ذلك مثل اصلاح التشوه الهيكلى تحدى من الناحية التقنية.

الاستنتاج: يعد تثبيت الفقرات القطنية مع الحوض وسيلة مؤثرة و امنة لعلاج كسور الفقرات العجزية الناتجة عن حوادث.