

Combined Approach for Cervical Schwannomas with Large Extraforaminal Extension

Hesham El Sobky, MD., Ashraf S Zidan, MD., Amin Sabry, MD.

Department of Neurosurgery, Faculty of Medicine, Mansoura University, Mansoura, Egypt.

ABSTRACT

Background Data: About 75% of spinal schwannoma are intradural, 10% intraextradural, and 15% completely extradural. These tumors are usually slowly growing and reach a large size before becoming symptomatic. The tumors which are totally or partially located in the epidural space (dumbbell tumors) are either intraspinal, foraminal, or extraspinal. These dumbbell tumors represent almost 18% of the total percentage of whole spinal schwannomas, but they are responsible for almost half of the cervical schwannomas. When these tumors have large extraforaminal part, total excision through a single approach might be difficult to achieve.

Study design: This is a retrospective clinical case study.

Purpose: To evaluate the efficacy and safety of combined approach for excision of these large tumors that are closely related to the vertebral artery.

Patients and Methods: This study was conducted in Mansoura University Hospital on six patients suffering from cervical spinal schwannoma with large lateral extraforaminal component. The mean age was 38 (range, 22–50) years. Two patients were males and four were females. All patients were assessed clinically and radiologically using CT and MRI cervical spine and vertebral artery angiography before surgery. Motor power was assessed according to MRC muscle power grading system. Posterior approach through a hemilaminectomy with facet preservation was used for excision of the intraspinal part, followed by the anterolateral approach to remove the extraspinal extension to avoid any manipulation to the vertebral artery. Perioperative data were reported and a routine postoperative MRI of the cervical spine was conducted. Patients were followed up at the outpatient clinic on a regular basis.

Results: Complete surgical excision of both tumor components were performed through combined posterior and lateral approach in all patients. Postoperative clinical assessment showed that all patients with radiculopathy improved; however, in two patients with weaknesses, one mildly deteriorated and the other remained the same, but both improved by physiotherapy. One patient developed wound CSF Leak after surgery, responding to frequent dressing and lumbar drain.

Address correspondence and reprint requests: Hesham El Sobky, MD.

Department of Neurosurgery, Faculty of Medicine, Mansoura University, Mansoura, Egypt

E-mail: h_espero@yahoo.com

Submitted: May 28th, 2019

Accepted: June 20th, 2019

Published: July, 2019

The article does not contain information about medical device(s)/drug(s).

No funds were received in support of this work.

The authors report no conflict of interest.

Conclusion: Cervical spinal schwannomas with large lateral extra foraminal component can be treated safely and effectively with combined posterior and lateral approaches to achieve complete surgical excision. (2019ESJ189)

Keywords: Cervical spine, dumbbell schwannoma, combined approach, surgical excision

INTRODUCTION

Schwannoma is a tumor that commonly affects the spinal cord and presents in many forms such as single, multiple (with or without neurofibromatosis), cystic, hemorrhagic, melanotic, and malignant. Almost 75% of spinal schwannomas are intradural, 10% extend in intradural and extradural spaces, and 15% are totally epidural.¹⁰ Lesions which are totally or partially located in the epidural space (dumbbell tumors) are either intraspinal, foraminal, or extraspinal. These dumbbell forms represent about 18% of spinal tumors and are responsible for almost half of cervical schwannomas.¹ In 18–36 % of all cervical schwannomas, the first and second cervical nerve roots are the most affected, with almost 85% and 15% being in epidural intradural locations, respectively.^{9,11}

Motor deficit is rare and usually patients present with radiculopathy and or myelopathy. Sphincteric disturbances and slowly growing neck mass are rare presentation.¹⁰

MRI is the standard diagnostic imaging modality that, in addition to its role in diagnosis and tumor localization, also helps in surgical planning. Schwannomas are usually solid tumors mostly seen in the dorsal sensory roots pushing the spinal cord to the opposite side. They are usually isointense on T1-weighted images and markedly hyperintense on T2-weighted images. Hemorrhage and calcifications are not common. A computerized tomography (CT) scan is also helpful in evaluating the bony erosion in foraminal and extraspinal extensions. It ranges from a limited widening of the intervertebral foramen to a large defect in one or several vertebral bodies and/or facet joints.²

Cervical schwannomas with large extraforaminal extension are a challenging problem due to the

fact that complete excision through a single approach is difficult, their relation to vertebral artery is intimate, and there is instability resulting from facetectomy. This study aims to evaluate safety and efficacy of combined approach in these lesions.

PATIENTS AND METHODS

This retrospective study was conducted in Neurosurgery Department, Mansoura University Hospital, from 2015 to 2018 on six patients who presented with cervical spinal schwannomas with large lateral extraforaminal component.

Thorough history was taken, including personal history, onset and progression of patient complaints, and symptoms suggesting motor, sensory, or sphincteric deficits; history suggesting associated neurofibromatosis and previous surgery for similar tumors; family history of similar conditions and neurofibromatosis. All patients were assessed clinically looking for café au lait patches or multiple subcutaneous lesions characteristic for multiple neurofibromatosis. A modified MRC scale was used to assess the motor power of the affected limb. Muscle tone and reflexes were assessed to detect myelopathic affection. Sensory examination was implemented to detect any deficits in the dermatomal distribution of the affected nerve roots.

Patients were submitted to X-ray, MSCT scan, and MRI with intravenous contrast of the cervical spine and neck to delineate the level, extension, and enhancement of the lesion and spinal cord displacement and compression and to identify the size, extension, and relation of the extraforaminal part to the surrounding structures. All our patients were subjected to routine preoperative evaluation and routine laboratory investigations.

Surgical Procedure

Surgery was done under general anesthesia. Patients were positioned in prone position with pillows below the chest and pelvis and head fixed with pins. The procedure steps were as follows: posterior midline skin incision was made, followed by unilateral subperiosteal muscle stripping and then hemilaminectomy without facetectomy. Microsurgical excision of the intraspinal part of the tumor was done; afterwards, hemostasis and water-tight dural closure were performed. Then, the wound was closed in layers without drainage. The patient was then repositioned to a supine position with head extended and turned to the opposite side of the tumor with a small pillow below the shoulder. A longitudinal skin incision at the posterior border of sternomastoid muscle was used to approach the extraforaminal part through the anterolateral approach. To dissect through the layers of the neck, we went through the platysma, dissected the posterior border of the sternomastoid muscle, and then identified and isolated the phrenic nerve which lies on the anterior surface of the scalenus anterior and this muscle was also dissected to approach the spinal foramina between its posterior border and the anterior border of the scalenus medius. The extraforaminal parts of the tumor were always large enough and pushing the surrounding structures such as nerves, vessels, and carotid sheath. We took care of the vertebral artery during the late stage of dissection and during extraction of the tumor from the foramen. After tumor removal, meticulous hemostasis, and wound closure in layers, a drain was inserted. Postoperatively, a hard neck collar was used for two weeks. All resected tumors were sent for histopathological examination to confirm diagnosis. All our patients underwent MRI with contrast of the cervical spine and neck to detect any residual tumor or postoperative changes. A physiotherapeutic program was applied for all patients presenting with motor deficits as

preoperative preparation and postoperative rehabilitation.

RESULTS

Of total six patients, two were males and four were females with mean age of 38 ± 16 (range, 22–50) years. Four patients were females and two were males. Preoperative clinical assessment of our patients showed that two patients presented with grade IV motor weakness and all patients suffered from radiculopathy. Four patients presented with tumors affecting left side and two patients affecting right side. C2 and C4 roots were the most more affected roots, each presenting in 2 patients. Five patients suffered from intraextradural type and one patient from completely extradural schwannomas. The mean operative time was 190 ± 39 (range, 160–220) minutes. There was no significant blood loss and we did not need blood transfusion in all procedures. The mean hospital stay was 3 ± 1.9 (range, 1–5) days. Postoperative clinical assessment showed that radiculopathy improved in all patients, whereas one of the two patients with grade IV motor weakness deteriorated after surgery to grade III and the other patient remained at the same grade; however, they both recovered and improved with postoperative physiotherapy. All patients had a follow-up MRI cervical spine and neck with intravenous contrast and in all our cases total excision was achieved (Table 1). Reported morbidity in this small series included one case which already had mild hydrocephalus preoperatively, experienced progression of hydrocephalus, and needed ventriculoperitoneal shunt insertion. Another patient developed CSF collection that improved after lumbar drain insertion which was removed after five days. At last, a patient suffered deterioration of motor power due to mild cord injury which was improved on steroid and physiotherapeutic program for two months.

Table 1. Demographic data of the patients.

Case	Age/sex	Presentation	Other	Level	Side	Relation to dura	Clinical outcome	Complications
1	35/F	Radiculopathy	NF1	C4	Right	Intraextradural	Improved	
2	47/F	Radiculomyelopathy MRC: grade IV	Hydrocephalus	C2	Left	Intraextradural	MRC: grade IV improved pain	Hydrocephalus
3	28/M	Radiculopathy		C3	Left	Extradural	Improved	
4	22/F	Neck mass	NF1	C4	Left	Intraextradural	Removed mass	
5	50/M	Radiculomyelopathy MRC: grade IV		C2	Left	Intraextradural	MRC: grade III	Deteriorated to grade III
6	46/F	Radiculopathy		C5	Right	Intraextradural	Improved	CSF collection, pseudomeningocele

NF1: neurofibromatosis type 1; MRC: Medical Research Council.

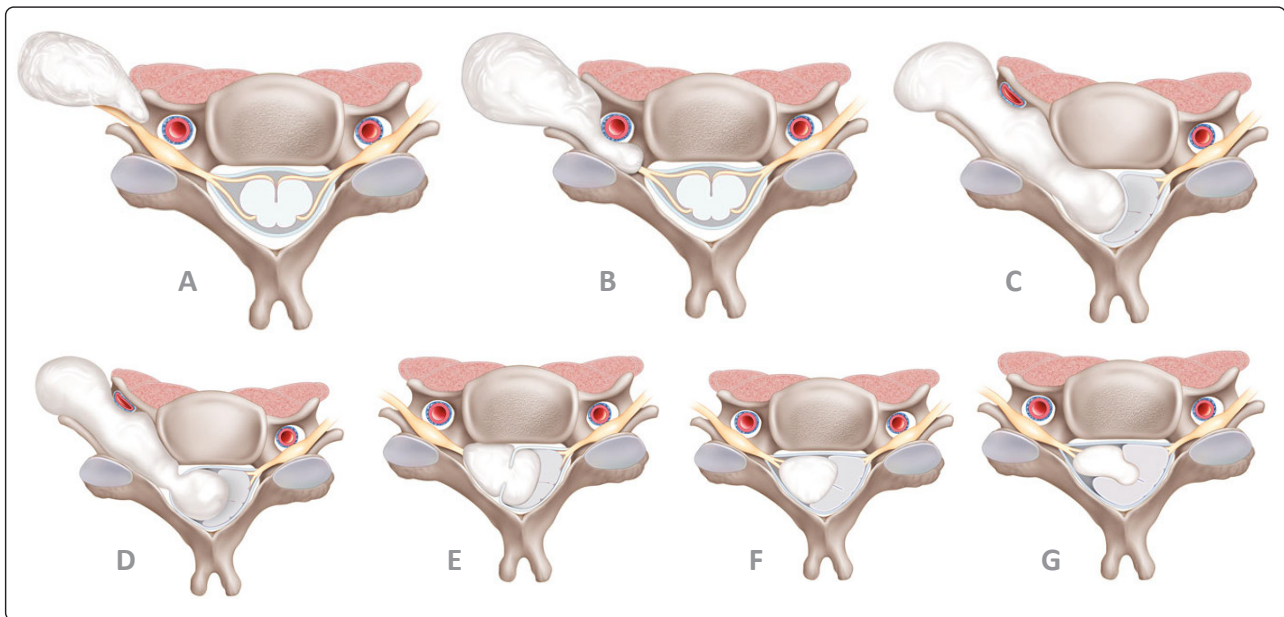


Figure 1. Types of peripheral nerve sheath tumors: (A) extraspinal; (B) extraspinal-foraminal; (C) (extraspinal-) foraminal-extradural; (D) (extraspinal-) foraminal-extradural-intradural extramedullary; (E) extradural-intradural extramedullary; (F) intradural extramedullary; (G) intradural extra- and intramedullary.³

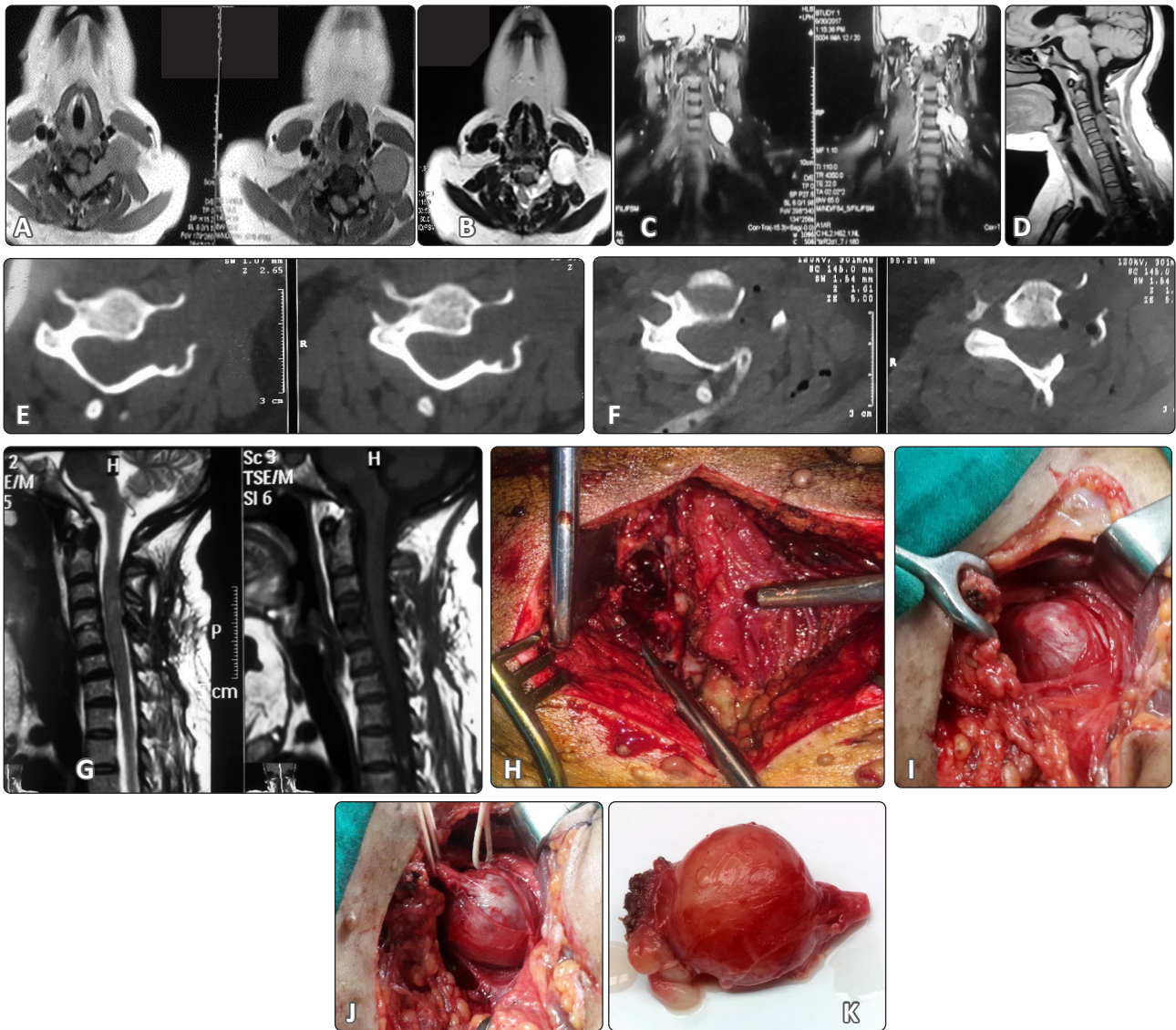


Figure 2. Case No. 4. Cervical MRI (A) T1 WI axial images; (B) T2 WI axial images (C); T2 WI coronal images showing left C4/5 dumbbell-shaped cervical schwannomas encroaching upon the cervical canal and widening the intervertebral foramen; (D) sagittal T1 WI showing the extent of intracanalicular portion. CT scan of cervical spine (E) preoperatively showing widened foramen transversarium and bony erosion; (F) early postoperative CT after hemilaminectomy. (G) Postoperative T2 WI MRI cervical spine showing complete tumor excision. (H) Intraoperative photo showing posterior approach after unilateral muscle stripping, hemilaminectomy, and intraspinal part excision. (I,J,K) Anterolateral exposure of the extraforaminal tumor portion with dissection identification of the lesion and of the phrenic nerve and then en bloc excision.

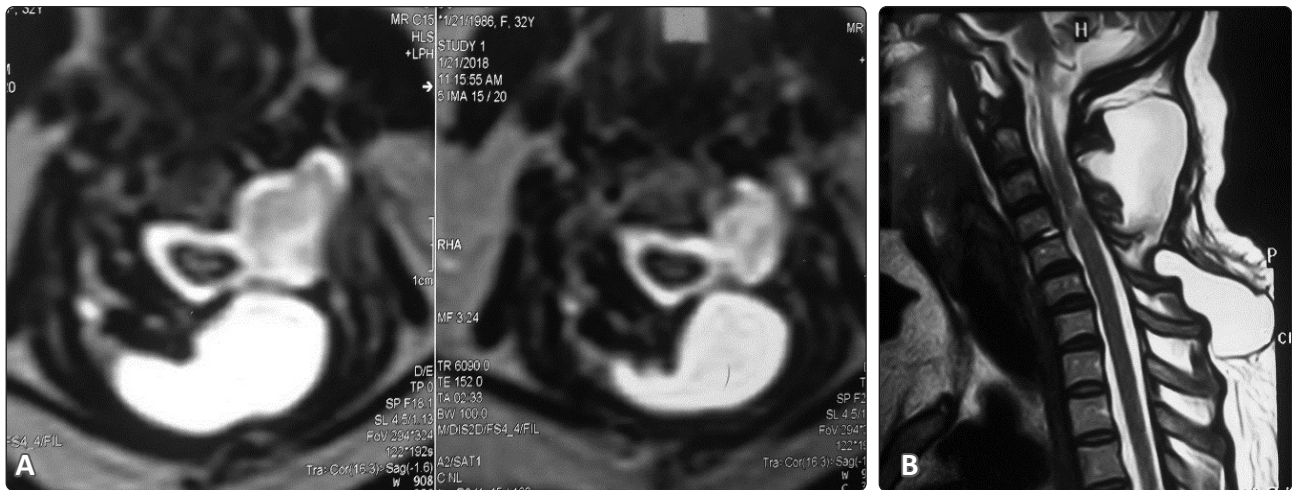


Figure 3. Case No. 6. Postoperative axial T2 II WI MRI cervical spine showing CSF collection. (A) Axial images showing CSF collection (pseudomeningocele) through the foramen and subcutaneous collection. (B) Sagittal image showing large subcutaneous CSF collection.

DISCUSSION

Spinal schwannomas represent about 30% of the primary tumors affecting the spinal cord. Schwannomas usually arise from the sensory nerve roots in 70% of cases, from the motor nerve roots in 20% of cases, and from combined sensory and motor origin in the rest 10% of the cases. Regarding their position according to the dura matter, 75% of schwannomas are subdural, 10% extend through both the subdural and epidural spaces, and 15% are totally epidural. In the cervical region, C2 spinal root is the most commonly affected site (15% of all spinal schwannomas) and the tumors are mostly epidural in position as reported by many studies. In this series, among the C1, C2, and C3 spinal schwannomas, 11 (71%) originated from C2 spinal nerve root. In cases of NF Type1, schwannomas usually present in multiple forms and the total incidence of schwannomas at any spinal level is reported in approximately 4% of cases.⁶

In our series, the most affected levels are C2 and C4 with percentage of 33.3% each. Multiple schwannomas were absent in our series. Male and female ratio was 1:2 and this is similar to other

authors who had reported a higher incidence of these tumors in females.⁵

In most cases, these tumors reveal moderate vascular infiltration and they are firm in consistency. These variants of schwannomas usually have a well-defined subdural arachnoid plane of dissection together with well-defined epidural capsule that makes them easier for surgical resection and this was similarly documented in our series.⁴

Despite the low risk of vertebral artery injury during surgical excision of schwannoma, it is recommended by many authors to provide effective proximal control of the vertebral artery before the surgery. On the contrary, based on the previous rule, other authors revealed that there is no role for intraoperative proximal or distal control of the vertebral artery.³ The dumbbell type tumors of schwannoma are usually associated with bony instability or deformity, so additional bony removal is required for complete removal of this type of tumor. Long-time follow-up is mandatory for early detection of any bone instability and once it occurs, it should be stabilized immediately.¹²

Anterolateral approach is recommended by many surgeons because it provides perfect resection of any component from extraspinal to intradural compartments with perfect control of the vertebral

artery without the need for any other method for fixation.⁷

These tumors are known for their critical location, with anterior and/or anterolateral extension to the spinal cord, and have a close relation to vital neural and vascular structures; meanwhile, their surgery is usually very rewarding. If the tumor anatomy in relation to normal surrounding structures is appropriately understood, then surgery of these bad-looking tumors is relatively easy and uncomplicated.⁸ This notation is also noted in our work.

In our series, combined approach for these tumors permits complete excision of the tumor. The intraspinal part is removed easily through hemilaminectomy with facet preservation and this will not interfere with spine stability. The intraspinal part is always small and originating from one side, so a hemilaminectomy approach is more than enough for its resection. Additionally, the large extraforaminal part is usually palpable through the skin and easily dissected from the surrounding structures. In this technique, we avoid any traction or aggressive manipulation on the vertebral artery during excision of the extraforaminal part.

The main limitation of this study was the small sample size. This is due to the limited number of cases presented to us with large extraforaminal extension which necessitates the use of combined approach as we usually use posterior approach for lesions with small extraforaminal extension.

CONCLUSION

Cervical spinal schwannomas with large lateral extraforaminal component can be treated safely and effectively with combined posterior and lateral approaches to achieve complete surgical excision.

REFERENCES

1. Altas M, Cerci A, Silav G, Sari R, Coskun K, Balak N, et al: Microsurgical management of non-neurofibromatosis spinal schwannoma. *Neurocirugia* 24:244–249, 2013
2. De Verdelhan O, Haegelen C, Carsin-Nicol B, Riffaud L, Amlashi SF, Brassier G, et al: MR imaging features of spinal schwannomas and meningiomas. *J Neuroradiol* 32:42–49, 2005
3. George B, Bruneau M, Spetzler RF: Pathology and surgery around the vertebral artery. Springer, Paris, Ed 2011, pp.165–200
4. Goel A, Muzumdar D, Nadkarni T, Desai K, Dange N, Chagla A: Retrospective analysis of peripheral nerve sheath tumors of the second cervical nerve root in 60 surgically treated patients. *J Neurosurg Spine* 8:129-134, 2008
5. Krishnan P, Behari S, Banerji D, Mehrotra N, Chhabra DK, Jain VK: Surgical approach to C1-C2 nerve sheath tumors. *Neurol India* 52:319-324, 2004
6. Kyoshima K, Uehara T, Koyama J, Idomari K, Yomo S: Dumbbell C2 schwannomas involving both sensory and motor rootlets: report of two cases. *Neurosurgery* 53: 436-440, 2003
7. Lot G, George B: Cervical neuromas with extradural components: surgical management in a series of 57 patients. *Neurosurgery* 41:813–822, 1997
8. McCormick PC: Surgical management of dumbbell tumors of the cervical spine. *Neurosurgery* 38:294–300, 1996
9. Safavi-Abbasi S, Senoglu M, Theodore N, Workman RK, Gharabaghi A, Feiz-Erfan I, et al: Microsurgical management of spinal schwannomas: evaluation of 128 cases. *J Neurosurg Spine* 9:40–47, 2008

10. Sun H, Tian H: Intraspinal tumors accompanied by hydrocephalus: case report, systematic review, and discussion of treatment strategy. *Neurologist* 17:342–345, 2011
11. Takami T, Yamagata T, Chokyu I, Ikeda H, Tsuyuguchi N, Ohata K: Surgery of spinal nerve sheath tumors originating from C1 or C2 of high cervical spine. *Neurol Med Chir* 50:1044-1049, 2010
12. Yong Yu, Xiaobiao Zhang, Fan Hu, Tao Xie, Ye Gu: Minimally invasive microsurgical treatment of cervical intraspinal extramedullary tumors. *J Clin Neurosci* 18: 1168–1173, 2011

الملخص العربي

استئصال أورام العمود الفقري العنقي الكبيرة الممتدة خارج القناة الشوكية بواسطة النهج الجراحي المشترك

البيانات الخلفية: خمسة وسبعون بالمائة من هذه الأورام يكون داخل الأم الجافية وعشرة بالمائة يتكون من جزء داخل الأم الجافية وجزء خارجها في حين أن خمسة عشر بالمائة يكون خارجها بشكل كامل . وهذه الأورام في الغالب تكون حميدة وبطيئة النمو وتصل لاحجام كبيرة قبل أن تسبب أعراض ملحوظة وعندما يكون لهذه الأورام أجزاء كبيرة خارج القناة الشوكية يصبح النهج الجراحي المشترك هو الوسيلة المثلى لاستئصالها.

تصميم الدراسة: دراسة مرجعية.

الغرض: لبيان مدى كفاءة وامن النهج الجراحي المشترك في علاج مثل هذه الاورام.

المرضى والطرق: اجريت هذه الدراسة في مستشفى جامعة المنصورة علي ستة حالات رجلين وأربعة سيدات كلهم يعانون من تلك الأورام. وقد اجريت لهم اشعات مقطعية ورنين مغناطيسي علي الفقرات العنقية واشعة مقطعية علي شرايين الرقبة قبل الجراحة. و قد تم استئصال الجزء داخل القناة الشوكية عن طريق مدخل جراحي خلفي تحفظي باذالة جزء من العظام الخلفية للفقرة العنقية التي يوجد الورم خلفها وذلك للحفاظ علي ثبات الفقرات. أما الجزء الآخر من الورم فقد تم استئصاله من خلال مدخل جانبي من الرقبة. وقد تم إجراء اشعات رنين مغناطيسي لكل الحالات للمتابعة.

النتائج: تم استخدام النهج الجراحي المشترك لاستئصال تلك الأورام استئصال كامل. وقد حدث في احدي الحالات تسرب للسائل النخاعي والذي تحسن بعد تركيب درنقة قطنية.

الاستنتاج: أورام العمود الفقري العنقي الكبيرة الممتدة خارج القناة الشوكية تحتاج إلي نهج جراحي مشترك لتحقيق الاستئصال الكامل مع الحفاظ علي الشريان وعلي ثبات الفقرات.