

Role of Posterior Interfacetal Distraction and Grafting in Complex Atlantoaxial Dislocation

Mohamed Ali El-Gaidi, MD., Mohamed Fawzy Khattab, MD.*

Neurosurgery Department, Faculty of Medicine, Cairo University, and Orthopedic Surgery Department*, Faculty of Medicine, Ain Shams University, Cairo, Egypt.

ABSTRACT

Background Data: Atlantoaxial fixation, unlike subaxial spine, is still challenging due to complex topographical anatomy. Nowadays, atlas lateral mass screws and transpedicular axis screws fixation is a well-accepted technique for the management of atlantoaxial instability due to their rigid fixation and higher fusion rate. However, in complex cases like basilar invagination, further reduction and proper bony alignment are needed.

Study Design: A retrospective descriptive clinical case series.

Objective: The aim of this study was to assess the safety and efficiency of bilateral posterior atlantoaxial facet joint distraction and insertion of spacer in reducing complex cases of atlantoaxial instability.

Patients and Methods: Out of 17 patients with atlantoaxial instability, five patients underwent posterior fixation and atlantoaxial facet joint distraction and insertion of spacer for reduction of irreducible atlantoaxial dislocation. Clinical results were evaluated by using the criteria of Japanese Orthopaedic Association Scoring System for Cervical Myelopathy (JOA score). The surgical technique, results, and morbidity and mortality were assessed.

Results: There were 3 females and 2 males; the age ranged from 10–50 years. The cause of significant instability was trauma (2 patients), while each of the 3 other patients suffered from Down syndrome, rheumatoid arthritis, and posttuberculous infection. All 5 patients had pyramidal tract compression manifestations. At the end of follow-up (mean 18 months), the average preoperative JOA score improved from 13.2 ± 1 to 15.9 ± 0.2 ($P=0.04$) and the average recovery rate was 69 ± 12 % SD. Postoperative CT scans showed that the mean atlantodens interval improved from 6.2 ± 1.6 to 1.8 ± 0.8 ($P=0.04$) and the mean clivus-canal angle increased from $119.8 \pm 3.7^\circ$ to $135.2 \pm 7^\circ$ ($P=0.04$). The average extra time and blood loss of bilateral facet distraction and grafting were about 65 minutes ($P=0.004$) and 72.5 ml, respectively. There was no mortality, vertebral artery injury, CSF leak, or construct failure.

Conclusions: Bilateral posterior atlantoaxial facet joint distraction and placement of spacer is a safe and effective adjunct procedure for reduction of complex atlantoaxial instability. (2019ESJ184)

Keywords: Atlantoaxial dislocation; basilar invagination; irreducible; facet joint distraction

Address correspondence and reprint requests: Dr. Mohamed Ali El-Gaidi, MD
Department of Neurosurgery 26, Faculty of Medicine, Kasr Al-Ainy Medical School, Cairo University,
Cairo 11562, Egypt - E-Mail: mohamedelgaidi@gmail.com

Submitted: June 1st, 2019
Accepted: June 26th, 2019
Published: July 2019

The article does not contain information about medical device(s)/drug(s).
No funds were received in support of this work.
The authors report no conflict of interest.

INTRODUCTION

Atlantoaxial instability (AAI) is characterized by excessive movement at the atlantoaxial articulation (C1 anterior arch and the odontoid process of C2, transverse ligament, as well as the facet joints bilaterally) due to either bony or ligamentous abnormality.¹⁹ The cause of this instability may be traumatic, inflammatory, degenerative, congenital, neoplastic, or idiopathic.^{2,5,9}

Unlike subaxial spine, atlantoaxial fixation is still challenging due to higher mobility and close proximity to the vertebral artery.^{1,2,6,21} Consequently, the posterior sublaminar wires/cables and interlaminar clamps were traditionally used.^{8,19} However, these techniques had lower fusion rates and require intact C1 posterior arch and C2 lamina and long postoperative rigid neck immobilization.¹⁹ Later, the C1-C2 posterior transarticular screw provided a more rigid fixation with higher fusion rate without postoperative halo vest immobilization.¹⁸ Nevertheless, it has a higher risk of vertebral artery injury and requires a perfect reduction of the C1-C2 articulation before insertion.¹

In 1994, Goel pioneered atlantoaxial fixation using C1 lateral mass screws and C2 pedicle screws with a plate construct via posterior approach.⁹ Harms popularized this procedure by using polyaxial screws and rod construct.¹² In contrast to transarticular screws, the lateral mass screws of C1 provide segmental fixation independent of axis and have less risk of vertebral artery injury.^{1,6,23}

Moreover, Goel upgraded the posterior approach by further facet joint distraction and placement of allograft revolutionizing the management of basilar invagination and the previously called irreducible atlantoaxial dislocation via a single-stage posterior approach. The distraction of the C1-C2 facets provided an opportunity to treat anterior cervicomedullary compression by reducing the basilar invagination.¹⁰

The anterior approach for atlantoaxial dislocation dates back to 1962 with initially

unacceptable high complication rate.⁷ Recently, the anterior retropharyngeal transarticular screws/lateral mass and C2 body screws and plate and endoscopic transnasal odontoidectomy are preferred to the transoral approach to avoid high infection rate.^{15,24} Although the perioperative complications were minimized with the advent of recent neurosurgical advances, the anterior approaches for atlantoaxial dislocation are still limited due to unfamiliarity of neurosurgeons and difficulty to extend fixation to clivus if atlanto-occipital fixation is required.¹⁷

In this study, the surgical technique and the results, including the complications, of five patients with irreducible atlantoaxial dislocation who underwent posterior fixation and bilateral atlantoaxial facet joint distraction and grafting were described.

PATIENTS AND METHODS

This was a retrospective study conducted in Al-Manial University Hospital, Kasr Al-Ainy Medical School, Cairo University, and El-Demerdash Hospital, Ain Shams University, during the period from October 2012 to December 2018. Out of 17 patients with atlantoaxial instability, five patients with irreducible atlantoaxial dislocation underwent posterior atlantoaxial screw fixation via atlas lateral mass screws and transpedicular screws of axis vertebra and bilateral atlantoaxial facet joint distraction and grafting.

Detailed patients' history was taken and they were subjected to full general and neurological examination. The Japanese Orthopaedic Association Scoring System for Cervical Myelopathy (JOA score)¹⁴ was utilized for clinical evaluation of the patient pre- and postoperatively. Preoperative radiographic investigations included plain X-ray cervical spine (anteroposterior, lateral neutral, and open-mouth views) and Computed Tomography (CT) scan with coronal and sagittal reconstruction and Magnetic Resonance Imaging (MRI) of cervical spine.

Unless patients presented with acute trauma, they underwent dynamic radiological investigations (flexion and extension views plain X-rays, CT, and/or MRI craniocervical junction) but not to the extent of causing neck pain or brachialgia or neurological deterioration and under medical supervision. The dynamic views were important not only to address the atlantoaxial instability

and elucidate the reducibility but also to exclude associated occult atlanto-occipital instability which necessitates extension of fixation to occiput. Postoperatively, plain X-rays (including dynamic views) and CT scans were routinely performed to assess the screws and reduction.

The recovery rate was calculated according to the following formula:¹³

$$\text{Recovery rate} = \frac{\text{Postoperative JOA score} - \text{Preoperative JOA score}}{\text{Normal score (17)} - \text{Preoperative JOA score}} \times 100$$

Statistical Analysis:

Data were statistically described in terms of mean \pm standard deviation (\pm SD), median and range, or frequencies (number of cases) and percentages when appropriate. Comparison of numerical variables between the study groups was done using the Mann–Whitney *U* test for independent samples. Within-group comparison of numerical variables was done using Wilcoxon's signed-rank test for paired (matched) samples. For comparing categorical data, Chi-square (χ^2) test was performed. Exact test was used instead when the expected frequency is less than 5. Two-sided *P* values less than 0.05 were considered statistically significant. All statistical calculations were done using computer program IBM SPSS (Statistical Package for the Social Science; IBM Corp, Armonk, NY, USA) release 22 for Microsoft Windows.

Surgical Technique:

The patient was placed in the prone position with a head holder in mild extension and under skull traction (7 kg or maximum of one-fifth of the total body weight in children),¹⁰ and the arms were tucked on both sides. The head was elevated up 15° to ease venous return. A midline skin incision was performed from below the external occipital protuberance to the 3rd cervical vertebra. The ligamentum nuchae was divided; occipitocervical musculature was stripped subperiosteally from the occipital bone and posterior arch of C1 and C2 lamina and retracted laterally exposing the lateral margin of C2/C3 facets bilaterally.

C2 neurectomy was done bilaterally to expose the C2 pars-interarticularis, the atlantoaxial joint, and the inferior articular facet of the lateral mass of atlas. At this stage, there was profuse venous bleeding from the venous plexus surrounding C2 roots which was controlled by bipolar coagulation and by using haemostatic agents. The entry point of C1 lateral mass screw was located at the center of the lateral mass of atlas with 15° medial and 15° cephalic angulations. The entry point for transpedicular screw was located at the lateral aspect of the C2 lateral mass, just caudal to the transition of the lateral mass into the C2 pars, with angulation of (25°–40°) medially and (15°–20°) rostrally (Figure 1A). Polyaxial screws of 3.5 mm diameter were used at C1 and C2 (Vertex, Medtronic Sofamor Danek, Memphis, Tennessee).

The rods were applied to the heads of the polyaxial screws with the axis screws being fully tightened. Bilateral distraction at the loose atlas lateral mass screws would open the atlantoaxial joints, resulting in progressive reduction. Cervical intervertebral spreader may be inserted at the C1-C2 facet if satisfactory distraction was not achieved. The articular facets of the C1-C2 joints were dissected bilaterally and the joint capsule was widely removed by using a microdrill, and pieces of bone grafts (autologous harvested from axis spinous process (3 cases) or artificial bone cement (polymethyl methacrylate) (2 cases)) were packed into the joints to enhance fusion and to maintain reduction. The bone cement was preferred if the

configuration of the facet joint was difficult and drilling was needed for bone graft insertion. The injected bone cement insinuated itself filling the facet space while saline irrigation was maintained to avoid increase temperature.

The height of spacer ranged from 3 mm to 6 mm according to the required height restoration. The instrumentation was finalized after removal of the distractors and removal of weight traction and the incision was closed in layers over a wound drain (Figure 1B).

Patients were discharged after 3–5 days and instructed to wear semirigid neck collar for 8 weeks and were followed up at outpatient clinic after 1 week when stitches were removed and after 2, 6, and 12 months. All patients underwent postoperative craniocervical junction CT imaging.

RESULTS

There was a slight female predominance (M/F=2/3) and the average age of patients at time of surgery was 31.6 ± 15.1 (range, 10–50) years. The average duration of symptoms was 19.6 ± 11.1 (range, 7–36) months. The cause of significant instability was trauma (2 patients), while each of the 3 other patients suffered from Os odontoideum (Down syndrome), rheumatoid arthritis, and posttuberculous infection. All 5 patients had pyramidal tract compression manifestations (quadripareisis in 3 patients and spasticity and precipitancy, one patient each). (Table 1)

The average operative time was 206 ± 34.4 (range, 160–240) minutes, and average blood loss was 360 ± 151.7 (200–600) ml. Compared to the other 12 cases with atlantoaxial fixation alone (without interfacetal distraction), the average operative time was 141.3 ± 21.3 (range, 115–

180) minutes ($P=0.004$), and average blood loss was 287.5 ± 118.9 (range, 150–450) ml ($P=0.24$, statistically insignificant). This means that the average extra time and blood loss of bilateral facet distraction and grafting were about 65 minutes and 72.5 ml, respectively. The average duration of follow-up after surgery was 18 ± 17.1 (range, 6–48) months. The average preoperative JOA score of the patients showed improvement from 13.2 ± 1 to 15.9 ± 0.2 at the final follow-up ($P=0.04$). The average recovery rate was $69\pm 12\%$ (range, 50–81.8%) (Table 1).

The position of 9 screws (90%) was satisfactory as noted on postoperative CT scans (Figure 3B), while one screw in one patient with rotational atlantoaxial instability, who experienced improvement of quadripareisis, was misdirected upward excessively and penetrated through both the lateral mass of atlas and the occipital condyle without injuring the hypoglossal nerve, vertebral artery, or any other structures, so revision surgery was not considered. Postoperative CT scans showed the mean atlantodens interval improved from 6.2 ± 1.6 mm to 1.8 ± 0.8 mm ($P=0.04$) and the mean clivus-canal angle increased from $119.8\pm 3.7^\circ$ to $135.2\pm 7^\circ$ ($P=0.04$).

Neither construct failure nor loosening of the screws was observed. No implant failure or sliding in flexion and extension was observed on the dynamic plain X-rays within the follow-up period. Mild occipital hypoesthesia was observed in one patient (20%) postoperatively due to C2 neurectomy, which decreased gradually in the follow-up period. None of the patients had excessive discomfort such as headache or neuralgia. No intraoperative mortality, vertebral artery injury, spinal cord injury, or cerebrospinal fluid leakage occurred during surgery.

Table 1. The preoperative clinical data and parameters for assessment of clinical and radiological outcomes of 5 patients with atlantoaxial instability who underwent atlantoaxial fixation and bilateral atlantoaxial facet joint distraction and insertion of spacer.

No.	Age	Sex	Diagnosis	Presentation	Duration/ month	JOAS pre-post (recovery)	ADI mm pre-post	CCA pre-post	Notes/ complications
1	10	M	Os odontoideum/ Down syndrome	Quadripareisis	24	13/16 (75%)	6-2	115°- 131°	-
2	28	M	Type II odontoid fracture	Neck pain, precipitancy	7	14/16 (66.7%)	5-2	125°- 139°	-
3	29	F	Tuberculosis/ basilar invagination	Quadripareisis	13	11.5-16 (81.8%)	6-1	121°- 142°	Penetration of occipital condyle
4	41	F	Type II odontoid fracture	Quadripareisis, neck pain	36	13.5-16 (71.4%)	9-3	118°- 125°	Occipital hypoesthesia
5	50	F	Rheumatoid/ arthritis basilar invagination	Spasticity	18	14.15.5 (50%)	5-1	120°- 139°	-

ADI: atlantodental interval; **CC Angle:** clivus-canal angle; **JOAS:** Japanese Orthopaedic Association Score.

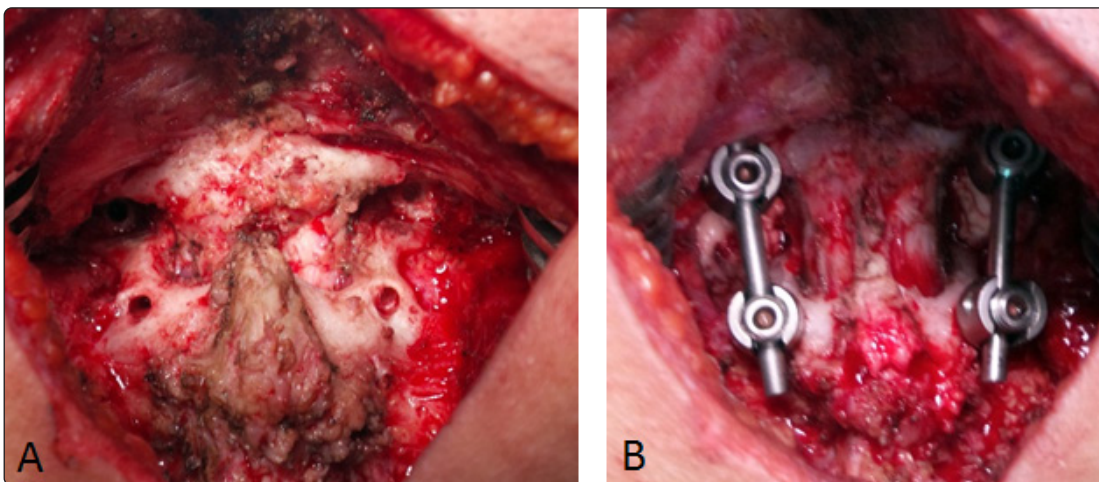


Figure 1. An intraoperative photograph demonstrating (A) the C1 lateral mass and C2 transpedicular screws entry points; (B) the final position of implant after facet distraction and cement insertion. Note the increased distance between the screws after distraction (patient no.1).

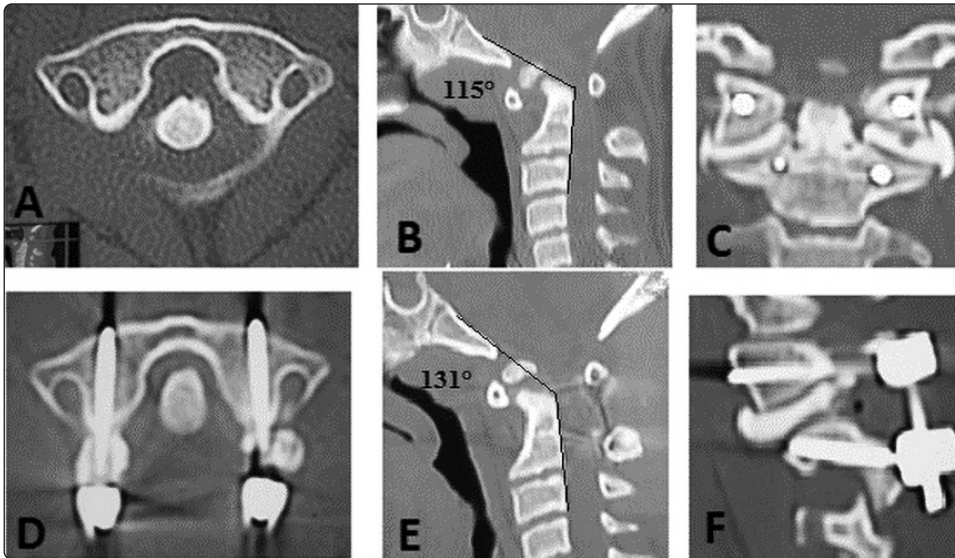


Figure 2. Pre- and postoperative CT scan of (patient no. 1). (A) Preoperative axial view of atlas with atlantodental interval = 6 mm; (B) preoperative sagittal view showing the encroachment of the craniocervical junction and clivus-canal angle; (C) postoperative coronal view revealing the bone cement at the facets bilaterally; (D) postoperative axial view of atlas showing the bicortical screws purchase and reduced atlantodental interval = 2 mm; (E) postoperative sagittal view noting the reduced dens and clivus-canal angle; (F) parasagittal view at the facet joint showing the bone cement at the facets.

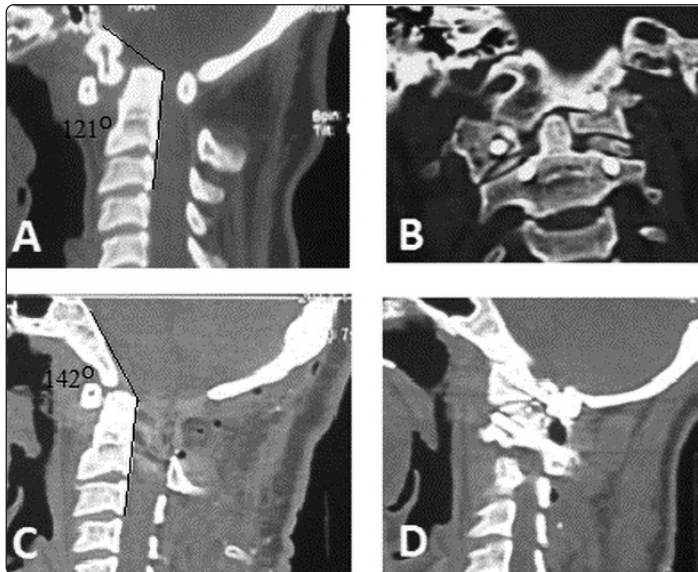


Figure 3. Pre- and postoperative CT scan of (patient no. 3). (A) Preoperative sagittal view noting the basilar invagination and compression of the craniocervical junction and cervicomedullary angle; (B) postoperative coronal view revealing the bone graft at the facets bilaterally, showing the penetration of left occipital condyle; (C) postoperative sagittal view showing the complete reduction of the dens and clivus-canal angle; (D) parasagittal view at the facet joint showing the bone graft at the facets.

DISCUSSION

Atlantoaxial dislocation was initially classified by Greenberg into two groups: reducible (type I) and irreducible according to dynamic X-rays.¹¹ Wang has further categorized the irreducible group into 3 subcategories according to skeletal

traction under anesthesia: atlantoaxial dislocation reducible after skeletal traction under anesthesia (type II), irreducible after skeletal traction under general anesthesia (type III), and irreducible (type IV) with evident anterior bony ankylosis (rare).²⁵ This classification offered surgical management protocols. Posterior fixation techniques are suitable for the reducible 2 types (I and II), while, for type

III, anterior release was recommended before posterior fixation. For type IV, odontoidectomy is required followed by either posterior or anterior atlantoaxial fixation.²⁵

Goel disputed the classification of irreducible atlantoaxial dislocation and challenged the necessity for the anterior release approach. He reported successful reduction and fixation of 22 patients with “fixed/irreducible atlantoaxial dislocation (type III)” who underwent posterior fixation and facet joint distraction and placement of allograft.¹⁰ This technique of C1-C2 facet joint manipulation and distraction may be considered a posterior release equivalent to the previously advocated anterior transoral release.

Bilateral C1-C2 facet distraction and interpositioning of bone graft or spacer into the joint space facilitates intraoperative reduction of irreducible dislocation and proper bony alignment.⁴ The possible mechanism is that the increased distance between C1-C2 facets after distraction automatically leads to a descent of the odontoid process out of the foramen magnum and a restoration of a better sagittal alignment, thus indirectly resolving the compression on the cervicomedullary junction in the majority of cases.¹⁶

Additionally, removal of the C1-C2 facet cartilage and decortication and interfacet impaction of bone graft or spacer enhances fusion due to widened contact area of graft under load and compressive forces of head weight and surrounding ligaments.²² Moreover, distraction of the C1-C2 interspace improves the stability of the atlantoaxial complex by increasing tension of ligamentous structures.⁴ The provided augmented stability precludes the need to extend the fusion to the occiput in many cases saving the atlantooccipital joint.

The proper size of graft should be determined preoperatively according to the required height restoration and confirmed intraoperatively to avoid C1-C2 facet over distraction and, consequently,

spinal cord stretch and damage. The reported height of graft ranged from 3 mm to 8 mm.^{10,16,22} Although no neurological complications were reported in Goel's 22 patients who underwent bilateral facet distraction and grafting, intraoperative neurophysiological monitoring was recommended.¹⁶

From biomechanical point of view, the insertion of spacers at C1-C2 facet combined with placement of a screw/rod construct resulted in further construct rigidity beyond the screw/rod technique. The spacers added significant stability compared to the screws and rods alone in both axial rotation and lateral bending which may be of paramount importance in patients with osteoporosis.²⁰

Various types of spacers were used at C1-C2 facet joints: autologous iliac bone graft or custom-made titanium spacers,¹⁰ polyetheretherketone cages,⁴ fibular graft,² demineralized bone matrix,²³ or bone cement.^{3,10} At the current study, corticocancellous autograft from the axis spinous process or bone cement was used.

In summary, upgrading the technique of posterior atlas lateral mass and axis screws/plating construct by further facet joint distraction and placement of graft has revolutionized the management of basilar invagination and the previously called irreducible atlantoaxial dislocation and should be considered when appropriate.

The main limitation of this study is the limited number of cases of fixed/irreducible atlantoaxial dislocation who underwent facet joint distraction and placement of graft. A further prospective study with more patients is recommended.

CONCLUSION

Bilateral posterior atlantoaxial facet joint distraction and placement of spacer is a safe and effective adjunct procedure during posterior atlantoaxial screw fixation for reduction of complex atlantoaxial instability.

REFERENCES

1. Abou-Madawi A, Solanki G, Casey AT, Crockard HA: Variation of the groove in the axis vertebra for the vertebral artery: implications for instrumentation. *J Bone Joint Surg Br* 79:820-823, 1997
2. Aryan HE, Newman CB, Nottmeier EW, Acosta Jr FL, Wang VY, Ames CP: Stabilization of the atlantoaxial complex via C-1 lateral mass and C-2 pedicle screw fixation in a multicenter clinical experience in 102 patients: modification of the Harms and Goel techniques. *J Neurosurg Spine* 8:222-229, 2008
3. Cacciola F, Patel V, Boszczyk B: Novel use of bone cement to aid atlanto-axial distraction in the treatment of basilar invagination: a case report and technical note. *Clin Neurol Neurosurg* 115(6):787-789, 2013
4. Chandra PS, Prabhu M, Goyal N, Garg A, Chauhan A, Sharma BS: Distraction, compression, extension, and reduction combined with joint remodeling and extra-articular distraction: description of 2 new modifications for its application in basilar invagination and atlantoaxial dislocation: prospective study in 79 cases. *Neurosurgery* 77:67-80, 2015
5. El-Gaidi M: Atlas lateral mass screw fixation in atlanto-axial instability, clinical case series. *Egyptian Spine Journal* 7:30-38, 2013
6. El-Gaidi M: Methods of segmental screw fixation of axis: a cadaveric and surgical study. *Egyptian Spine Journal* 18:5-14, 2016
7. Fang H, Ong G: Direct anterior approach to the upper cervical spine. *J Bone Joint Surg* 44(8):1588-1604, 1962
8. Gallie W: Fractures and dislocations of the cervical spine. *Am J Surg* 46:495-499, 1939
9. Goel A, Laheri V: Plate and screw fixation for atlantoaxial subluxation. *Acta Neurochir (Wien)* 129:47-53, 1994
10. Goel A: Treatment of basilar invagination by atlantoaxial joint distraction and direct lateral mass fixation. *J Neurosurg Spine* 1:281-286, 2004
11. Greenberg AD: Atlanto-axial dislocations. *Brain* 91(4):655-684, 1968
12. Harms J, Melcher RP: Posterior C1-C2 fusion with polyaxial screw and rod fixation. *Spine* 26:2467-2471, 2001
13. Hirabayashi K, Miyakawa J, Satomi K, Maruyama T, Wakano K: Operative results and postoperative progression of ossification among patients with ossification of cervical posterior longitudinal ligament. *Spine (Phila Pa 1976)* 6:354-364, 1981
14. Japanese Orthopaedic Association: Scoring system (17-2) for cervical myelopathy. *J Jpn Orthop Assoc* 68:490-503, 1994
15. Kassam AB, Abla A, Snyderman C, Carrau R, Spiro R: An endoscopic transnasal odontoidectomy to treat cervicomedullary compression with basilar invagination. *Neurosurgery* 8(4):198-204, 2005
16. Kim IS, Hong JT, Sung JH, Byun JH: Vertical reduction using atlantoaxial facet spacer in basilar invagination with atlantoaxial instability. *J Korean Neurosurg Soc* 50(6):528-531, 2011
17. Lesoin F, Autricque A, Franz K, Villette L, Jomin M: Transcervical approach and screw fixation for upper cervical spine pathology. *Surg Neurol* 27(5):459-465, 1987
18. Magerl F, Seemann PS: Stable posterior fusion of the atlas and axis by transarticular screw fixation, in Kehr P, Weidner A (eds): *Cervical Spine*. New York, Springer, 1986, pp 322-327
19. Menendez JA, Wright NM: Techniques of posterior C1-C2 stabilization. *Neurosurgery* 60 (Supp11): S103-111, 2007

20. Park J, Scheer JK, Lim TJ, Deviren V, Ames CP: Biomechanical analysis of Goel technique for C1-2 fusion. J Neurosurg Spine 14:639-646, 2011
21. Rocha R, Safavi-Abbasi S, Reis C, Theodore N, Bambakidis N, de Oliveira E, et al: Working area, safety zones, and angles of approach for posterior C-1 lateral mass screw placement: a quantitative anatomical and morphometric evaluation. J Neurosurg Spine 6:247-254, 2007
22. Salunke P, Sahoo SK, Deepak AN, Ghuman MS, Khandelwal NK: Comprehensive drilling of the C1-2 facets to achieve direct posterior reduction in irreducible atlantoaxial dislocation. J Neurosurg Spine 23:294-302, 2015
23. Simsek S, Yigitkanli K, Seckin H, Akyol C, Belen D, Bavbek M: Freehand C1 lateral mass screw fixation technique: our experience. Surg Neurol 72:676-681, 2009
24. Wang J, Zhou Y, Zhang Z, Li C, Zheng W, Zhang Y: Minimally invasive anterior transarticular screw fixation and micro endoscopic bone graft for atlantoaxial instability. Eur Spine J 21(8):1568-1574, 2012
25. Wang S, Wang C, Yan M, Zhou H, Dang G: Novel surgical classification and treatment strategy for atlantoaxial dislocations. Spine (Phila Pa 1976) 38(21):E1348-E1356, 2013

الملخص العربي

دور تباعد المفصلين الجانبيين خلفيا مع وضع طعم عظمي في حالات التقلقل الفهقي المحوري المعقدة
البيانات الخلفية: مازال تثبيت فقرتي الفهقة والمحور (الفقرتين الاولى والثانية العنقية) يشكل تحديا، بخلاف الفقرات العنقية الأخرى، وذلك لتعقد الوضع التشريحي. حاليا يتم تثبيت الفهقة والمحور خلفيا بواسطة براغي مع قضيبين لقوة التثبيت وزيادة معدل الالتحام. لكن يتم الاحتياج لمزيد من رد التقلقل للوصول للوضع العظمي الطبيعي في بعض الحالات المعقدة.

الغرض: تقييم كفاءة وأمان تباعد المفصلين الجانبيين خلفيا مع وضع طعم عظمي في رد حالات التقلقل الفهقي المحوري المعقدة

تصميم الدراسة: هذا البحث هي دراسة استيعادية سريرية.

المرضى والطرق: تضمنت هذه الدراسة 5 حالات متعسرة الرد من بين 17 مريض يعانون من تقلقل فقرتي الفهقة والمحور. وقد تم تقييم النتائج السريرية طبقا لمعايير الجمعية اليابانية للعظام لاعتنال الحبل الشوكي العنقي.

النتائج: تراوح عمر المرضى بين 10 الي 50 عاما، وهم ذكران و 3 اناث. سببت الحوادث حالتين فقط من التقلقل الفهقي المحوري والحالات الأخرى عانت من البله المنغولي، الروماتويد والدرن، واشتكي جميع المرضى بدرجات متفاوتة من أعراض الضغط علي القناة الهرمية. وقد تم تركيب 10 براغي بنجاح ولكن احدثهم وصل الي اللقاح القذالي بدون مضاعفات، وقد تحسن التقييم السريري للمرضى من 13.2 نقطة الي 15.9 نقطة حسب معايير الجمعية اليابانية للعظام، وكان متوسط معامل التحسن %69، وتحسنت ايضا المعايير الاشعاعية بعد الجراحة. وبفضل الله لا توجد وفيات، مضاعفات عصبية أو اصابه للشريان الفقاري ولكن حدثت مضاعفات بسيطة مثل التمثل القذالي وتم علاجه تحفظيا.

الاستنتاج: ان تثبيت الفهقة والمحور خلفيا وتباعد المفصلين الجانبيين مع وضع طعم عظمي طبيعي أو صناعي وسيله امنه وفعاله وقليلة المضاعفات لمرضى التقلقل الفهقي المحوري مُتَعَسَّرُ الرَّدِّ.