

# Povidone–Iodine 3.35% Solution versus Normal Saline for Irrigation in Lumbar Fusion Surgery: A Retrospective Study

Ahmad FA Allam MD., MRCS<sup>1</sup>, Tarek AA Abotakia MD.<sup>1</sup>, Mahmoud YI Farghally MD.<sup>2</sup>

<sup>1</sup>Orthopaedic Department, Minia University Hospitals, Minia, Egypt.

<sup>2</sup>Orthopaedic Department, Alexandria University Hospitals, Alexandria, Egypt.

## ABSTRACT

**Background Data:** Povidone-iodine is very effective broad spectrum antiseptic solution against different types of pathogens including methicillin-resistant *Staphylococcus aureus* and some strains of *Enterococcus faecium* based on the antiseptic properties of iodine.

**Purpose:** To evaluate the effect of intraoperative 3.35 % povidone-iodine irrigation in lumbar spine fusion surgeries.

**Study Design:** Retrospective clinical case study.

**Patients and Methods:** 93 spine fusion surgeries in 2016 (Group I) and 112 fusion surgeries in 2017 (Group II). Both groups were retrospectively compared regarding infection rate, fusion rate, and Oswestry Disability Index (ODI) score. Group I had intraoperative saline irrigation and Group II was irrigated with 3.35 % povidone-iodine.

**Results:** There were no reported infections in Group II. Two superficial and two deep wound infections were observed in Group I. Complete wound dehiscence was found in one patient with deep wound infection. The pathogens were methicillin-resistant *Staphylococcus aureus* in two cases, *Klebsiella pneumonia* in one case, and combination of methicillin-sensitive *Staphylococcus aureus* and *Staphylococcus epidermidis* in the last case. There was insignificant difference between the two groups in fusion rates and with no linear correlation relationship between povidone-iodine soaking time and the fusion rate in Group II. There was significant postoperative ODI improvement in the two groups relative to the preoperative scores with insignificant statistical difference when comparing this improvement of the two groups.

**Conclusion:** Povidone-iodine 3.35% irrigation in lumbar spine fusion surgery is effective in decreasing postoperative infection with no negative influence on the fusion rate or clinical outcome. (2019ESJ177)

**Keywords:** Povidone-iodine 3.35%; wound irrigation; lumbar spine fusion

Study has been approved by the Research Ethics Committee, Minia University.

Address correspondence and reprint requests: Ahmad Fouad Abdel Baki Allam, MD, MRCS.

Orthopaedic Department, Faculty of Medicine, Minia University, Egypt.

E-mail: afallam@mu.edu.eg

Submitted: January 1<sup>st</sup>, 2019

Accepted: March 29<sup>th</sup>, 2019

Published: April 2019

The article does not contain information about medical device(s)/drug(s).

No funds were received in support of this work.

The authors report no conflict of interest.

## INTRODUCTION

One of the main sources of wound infection is the air-borne bacteria in the operation room that can reach the surgical wound through air-borne particles or fallen debris. Beside the parenteral antibiotics, this incidental contamination could be cleared with intraoperative wound irrigation using saline, antibiotic solution, or povidone-iodine solution.<sup>16,18</sup> Choosing an appropriate solution is one of the most important steps in wound irrigation. Normal saline is the most commonly used solution for wound irrigation with the lowest toxicity. Its principle is to dilute not to cleanse contaminants.<sup>9,22</sup>

Povidone-iodine is very effective broad spectrum antiseptic solution against different types of pathogens including highly resistant gram-positive bacteria, such as methicillin-resistant *Staphylococcus aureus* (MRSA) and some strains of *Enterococcus faecium* based on the antiseptic properties of iodine.<sup>15</sup>

The aim of the current study was to evaluate the effect of intraoperative 3.35% povidone-iodine irrigation in lumbar spine fusion surgeries regarding infection rate, fusion rate, and clinical score using Oswestry Disability Index (ODI).

## PATIENTS AND METHODS

The study was approved by the Institutional Research Ethics Committee. From January 2016 to December 2016, 93 consecutive spine fusion surgeries were performed including 163 primary instrumented lumbar/lumbosacral levels (Group I), while, in 2017 from January to December, 112 consecutive primary instrumented lumbar/lumbosacral fusion surgeries with 199 levels were done (Group II).

Surgical indications were lumbosacral degenerative stenosis and/or segmental instability. Patients with rheumatoid arthritis, infectious spondylitis, ankylosing spondylitis, an immune suppressive treatment, patient who had incidental

dural tears, and patients who had previous spinal surgery were excluded from the study.

The operative procedures were TLIF and/or posterolateral instrumented fusion using transpedicular screw fixation system. Informed written consent was signed before participating in the study in Group II. For Group I, the informed written consent for surgery had an additional approval for the use of all data for any upcoming research studies.

All the operations were performed under the same conditions, the same surgical team, the same surgical technique under the same standard operative environment, and the same operating theatre temperature and humidity ranges without laminar flow or body-exhaust suits. Standard aseptic procedures were applied for the skin using povidone-iodine, sterile drapes, and clothes. Gloves were replaced every 2 hours by new pairs.

In Group I, surgical wounds were irrigated prior to bone grafting with normal saline without any additions; the wound was filled and soaked with normal saline; then suction was performed and then soaking and suction were repeated three times. In Group II, provided that dural integrity was preserved and prior to decortication and bone grafting, surgical wounds were irrigated with 3.35 % povidone-iodine solution enough to fill the wound soaking it for few minutes according to the operative time followed by irrigation with normal saline as in Group I.

The time of wound soaking by povidone-iodine solution before suction was variable according to the time of surgery: 1-minute soaking/1 hour of surgical time (soaking time in minutes = surgical time in hours). As this concentration is not commercially available, 3.35 % povidone-iodine solution was prepared by mixing 100 ml of 10% povidone-iodine and 200 ml of normal saline.

Decortication using high speed burr and iliac bone grafting were subsequently done with no more irrigation. Wound was closed in layers and suction drain was applied that was removed in 48 or 72 hours postoperatively when the drained volume in 24 hours was less than 50 ml. According to the infection control unit guidelines in the authors' hospital, preoperative

intravenous (1500 mg) amoxicillin-clavunate was administered 30 minutes prior to surgery that was repeated every 3 operative hours; then additional amoxicillin-clavunate (1500 mg/12 h) was given for 72 h postoperative and then oral amoxicillin-clavulanate (1000 mg/12 h) for 7 days. Any patients allergic to the amoxicillin received other antibiotics accordingly.

According to infection control unit in our hospital, infection was identified following Centers for Disease Control and Prevention (CDC) criteria for surveillance of Surgical Site Infection (SSI) 2010.<sup>20</sup> There was no difference between the two groups in any infection control cointerventions; both groups have the same antibiotic protocol, diabetic follow-up protocol, and dressings.

Any risk factors for infection such as diabetes mellitus and conditions of immunodeficiency were recorded. Infection was suspected with fever and unusual back pain at the site of the operation, and white blood cell count, erythrocyte sedimentation rate, and C-reactive protein were requested in addition to microbiological cultures from the surgical wounds.

Follow-up was as follows: all patients were planned to be followed up for at least 12 months regarding infection rates and clinical scoring using ODI at 2 weeks, 6 weeks, 3 months, and 6 months. Fusion was assessed at 3, 6, 9, and 12 months of follow-up on plain anteroposterior, lateral, and flexion/extension radiographs. Interbody fusion was considered sound if there were no radiolucent lines, no segment motion, and remodeling of graft with trabeculation and density equal to adjacent vertebrae. In posterolateral fusion, if mature bridging trabeculae with remodeling, no radiolucent lines, and no segment motion on flexion/extension films were reported on radiographs, fusion was considered sound.<sup>17</sup> Fusion was assessed by one musculoskeletal radiology consultant and 3 spine surgeons; two of them were involved in the surgeries.

The recorded clinical data of both groups were compared retrospectively. No a priori power analysis was done. Statistical analysis was done using SPSS, 16 (SPSS Inc., IL, USA). P values less than 0.05 were considered statistically significant.

## RESULTS

During follow-up, 3 patients were lost in Group I versus 6 patients in Group II, so the statistical analysis was done on 90 patients (Group I) versus 106 patients (Group II). The mean follow-up was  $15.3 \pm 1.9$  months in Group I and  $12.1 \pm 2.3$  months in Group I. The demographic and operative data are summarized in Table 1. In Group I, thirteen patients had diabetes mellitus (DM) and fifteen were smokers, while in Group II, twenty patients had DM and twenty-three were smokers with insignificant statistical differences. There were two superficial and two deep wound infections in Group I during the first 2 weeks postoperatively; complete wound dehiscence was found in one patient with deep wound infection in Group I. No infections were reported in Group II.

These four infected patients were operated upon for degenerative stenosis with instability. MRSA was cultured from two diabetic patients and *Klebsiella pneumonia* from one nondiabetic patient, and the last patient infection was caused by combination of methicillin-sensitive *Staphylococcus aureus* and *Staphylococcus epidermidis* and this patient was diabetic and heavy smoker with 23-year history of smoking. All infected patients were treated with thorough debridement and parenteral antibiotics (according to culture/sensitivities) for 6 weeks and then orally for another 6 weeks with strict blood glucose level control in the three diabetic patients. None of them required repeated debridement or implants removal. Complete eradication of infection of all patients was proved by decreasing serial C-reactive protein tests until a negative result and negative microbiological cultures from the surgical wound swabs.

Satisfactory outcome was reached in three patients, while one of the deep infection cases continued to have sciatica with VAS score of 3. His postoperative MRI showed no neurological compression, no implant loosening, and no evidence of fusion at 12-month follow-up. Sciatica improved at 15 months (VAS=0) and incomplete fusion was seen in his plain radiograph at 18-month follow-up.

At 12-month follow-up, 81/90 (90%) patients had complete radiographic fusion in Group I versus 97/106 (91.5%) in Group II (P=0.052). Posterolateral fusion was recorded in 49/56 (87.5%) in Group I versus 52/58 (89.6%) in Group II (P=0.266). TILF plus posterolateral fusion was recorded in 32/34 (94.1%) in Group I versus 45/48 (93.75%) in Group II (P=0.261) (Table 2). Correlation study between the povidone-iodine soaking time and the fusion rate in Group II

showed no linear relationship as the correlation coefficient equal zero (P=0.5) (Figure 1).

ODI Scoring showed significant postoperative improvement in the two groups relative to the preoperative scores (P<0.0001) (Figure 2). ODI improvement was formulated as follows: [pre ODI – post ODI], comparing this improvement of the two groups showed insignificant statistical difference (P=0.374) (Table 2). There were no postoperative new neurologic deficits in both groups.

**Table 1.** Demographic and operative data of the two patient groups.

Parameters		Group I (N=90)	Group II (N=106)	P
Age/years		44.01±8.9 (29-59)	47.52±9.2 (31-62)	0.006**
Male/female		39: 51	49: 57	0.775*
Operated levels		157	185	0.954**
Diabetes mellitus		13/90	20/106	0.53*
Smokers		15/90	23/106	0.211*
Surgery	Posterolateral fusion	56	58	0.292*
	TLIF and posterolateral fusion	34	48	0.292*
Operative time/minutes		115.5±35.9	118.5±37.1	0.411**
Blood loss/ml		588.8±167.9	554.9±156.4	0.140**

\*Chi- square x2-test, for categorical data; \*\*Mann–Whitney U test: for nonparametric quantitative data; significant if p value<0.05.

**Table 2.** Comparison between the two groups regarding the postoperative outcome.

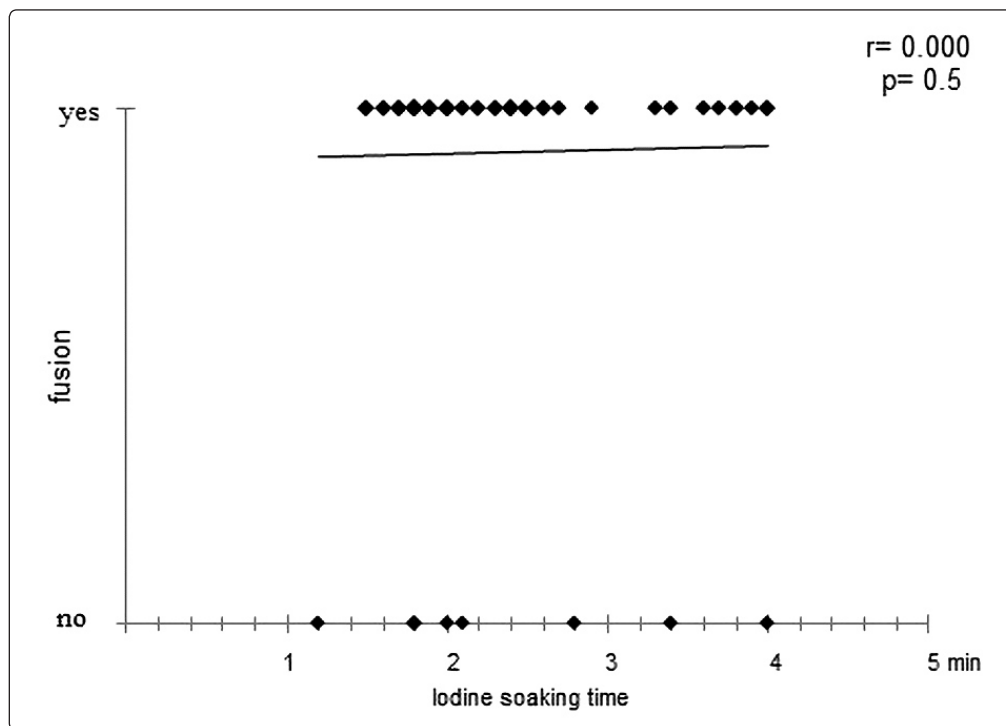
Parameters	Group I (N=90)		Group II (N=106)		P
Infection rate % (total)	4(4.4%)		0		0.029**
Superficial infection	2(2.2%)		0		
Deep infection	2(2.2%)		0		
Fusion rate % (total)	81/90 (90%)		97/106 (91.5%)		0.052*
Posterolateral	49/56 (87.5%)		52/58 (89.6%)		0.266*
Posterolateral+ TILF	32/34 (94.1%)		45/48 (93.75%)		0.261*
Pre-ODI	29.4±5.6	P<0.0001**	29.8±6.1	P<0.0001**	0.751**
Post-ODI	7.75±4.1		8.91±4.5		0.083**
ODI improvement	21.69±6.2		20.99 ±5.9		0.374**

\*Chi- square x2-test, for categorical data; \*\*Mann–Whitney U test: for nonparametric quantitative data; significant if p value<0.05.

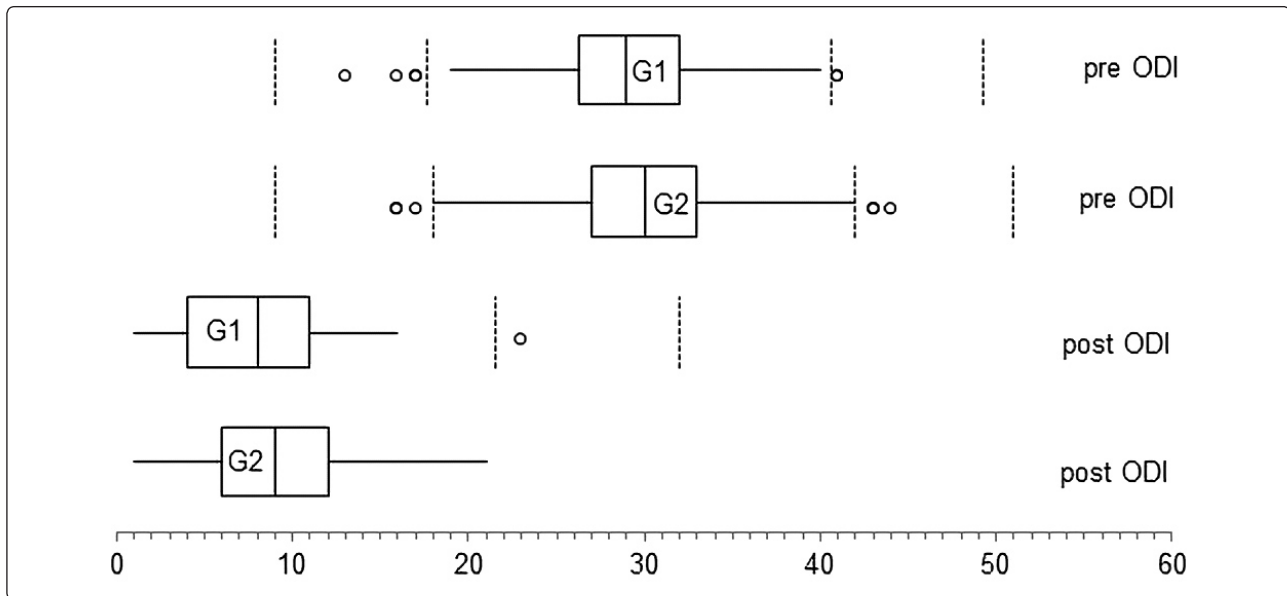
**Table 3.** Summary of previous studies of povidone-iodine irrigation in different surgical procedures.

Study	Irrigation solutions	Concentration	Surgical intervention	Infection rate	P	Others
Stroecker et al. <sup>13</sup>	Diluted PI versus no lavage	Not provided	Lumbar disc surgery	0.8% PI versus 2.4% without lavage	NA	
Angelini et al. <sup>14</sup>	Diluted PI versus no lavage	Not provided	Cardiovascular surgery	0% PI versus 22.7% without lavage	Significant	
Ko et al. <sup>15</sup>	0.5% PI versus NS	0.5%	Cardiovascular surgery	1.1% PI versus 0.6% normal saline	Insignificant	
Chang et al. <sup>16</sup>	0.35% PI versus NS	0.35%	Spine surgeries	0% PI versus 4.8% normal saline	Significant	No significant difference in fusion rate, improvement of pain score, function score
Patel et al. <sup>17</sup>	50:50 of 7.5% PI and NS versus gentamycin in NS	50:50 of 7.5% PI and normal saline (~3.75% PI)	Cranial surgery	2.6% PI versus 3.8% in the gentamycin group	Insignificant	
Ulivieri et al. <sup>18</sup>	6.15% PI-H <sub>2</sub> O <sub>2</sub> mixture versus no lavage	6.15%	Spine surgeries	0% PI-H <sub>2</sub> O <sub>2</sub> versus 1.5% without lavage	NA	

PI=povidone-iodine, NS=normal saline, and NA=not available



**Figure 1.** Scatter plot of correlation between povidone-iodine soaking time and fusion rate in Group II shows no linear relationship (correlation coefficient=zero).



**Figure 2.** Box plot of pre- and postoperative ODI scores shows great variation between the pre- and postoperative scores in each group and the preoperative scores are comparable in both groups and so do the postoperative scores. Right and left whiskers represent 1.5 times and -1.5 times interquartile range; right and left hinges represent 25% and 75% quartiles; middle represents median or 50% quartile.

## DISCUSSION

Postoperative infection in spine surgery is a devastating complication. It may range from less than 1% to around 10% especially with instrumentation even with strict sterile techniques.<sup>14,23</sup> Wound irrigation has been widely used with or without antibiotic or antiseptic solutions; however, there is no consensus or universal guidelines for its use in infection control programs for prevention of surgical site infections.<sup>10,12</sup> In 1980, the effect of wound irrigation using povidone-iodine was studied in gynecologic operations without preoperative prophylactic antibiotics. The study found no significant reduction in wound infections; the concentration of povidone-iodine was not provided.<sup>6</sup> Experimental exposure of postdurotomy spinal cord to 0.1% povidone-iodine was found to be neurotoxic. It could cause marked hypoxic myelin/axonal degeneration; thus 0.1% povidone-iodine solution should be avoided in wound dressing over any neural structures.<sup>1</sup>

In the current study, all the patients received the same preoperative regimen of prophylactic

antibiotics and all the patients who had dural tears were excluded to ensure the safety of the neural tissues. Many studies were conducted using povidone-iodine for wound irrigation in different surgical procedures with different concentrations (Table 3).

### **Studies did not provide povidone-iodine concentration:**

In lumbar disc surgery, 0.8% infections rate was recorded with intraoperative lavage of diluted povidone-iodine versus 2.4% infections rate without lavage; however, the study did not provide the concentration of povidone-iodine solution.<sup>19</sup> In another study on cardiovascular surgery, povidone-iodine irrigation (concentration not provided) was used after repeat sternotomy for postoperative hemorrhage, and no infections were found with povidone-iodine irrigation and 5 out of 22 (22.7%) patients were infected in the non-irrigated patients ( $P < 0.05$ ).<sup>2</sup>

### **Studies used povidone-iodine concentration < 1%:**

Intraoperative irrigation in cardiopulmonary bypass surgery was studied from July 1987 to June 1989 comparing povidone-iodine 0.5% with normal saline 0.9%. The infection rate of sternotomy wound was 1.1% in povidone-iodine

group versus 0.6% and in normal saline group, this difference was insignificant ( $P=0.16$ ).<sup>8</sup> Another study compared 0.35% povidone-iodine irrigation versus normal saline in spine surgeries and found a significantly higher infection rate in the normal saline group; 6 out of 124 (4.8%) patients had deep infections versus no infection in the povidone-iodine group ( $P<0.05$ ).<sup>4</sup>

***Studies used povidone-iodine concentration > 1%:***

In New York Presbyterian Hospital, a retrospective study was conducted on cranial neurosurgical procedures; wounds were irrigated prior to closure either with 150 cc of gentamycin (80 mg) diluted in 1 liter normal saline or with 150cc diluted betadine mixture 50:50 of 7.5% povidone-iodine and normal saline followed by 150 cc of diluted gentamycin (80 mg). At 1-month follow-up there was no difference in infection rate (1.7% in each group). However, at 90 days, the betadine group had 33% decrease in infection rates: 2.6% versus 3.8% in the antibiotic; group but the P value was insignificant ( $P=0.527$ ). They recommended a larger sample size study for a significant difference.<sup>13</sup>

Wound irrigation in spine surgery was studied using povidone-iodine and hydrogen peroxide solution composed of 10 cc of povidone-iodine 10%, 5 cc of H<sub>2</sub>O, and 1 cc of H<sub>2</sub>O<sub>2</sub> that is equal to 16 cc of povidone-iodine 6.15%. This study recorded no postoperative infections compared to 7 out of 460 (1.5%) cases in non-irrigated group and considered it effective in reducing the infection rate in spine surgery. However, there was no comment on the fusion rate.<sup>21</sup> The current study used 3.35% povidone-iodine solution for irrigation with no infection 0% versus 4.4% with normal saline irrigation. Although our methods for identification of infection were not prospectively assessed and this might be prone to error, however, our infection control unit strictly followed the Centers for Disease Control and Prevention (CDC) criteria for Surgical Site Infection (SSI) 2010 that was not changed during our study.<sup>20</sup>

In an experimental study, embryo chick osteoblast was exposed to different concentrations of Betadine (povidone-iodine) solution ranging

from 0.5 to 100% and stated that all povidone-iodine concentrations were cytotoxic to chick osteoblast except the 0.5% solution.<sup>7</sup> By contrast, iodine was claimed to have the ability to activate cytokine secretion from monocytes and macrophages, which in turn stimulate mesenchymal stem cell differentiation into osteoblasts through transforming growth factor- $\beta$ -1.<sup>3,11</sup> It was found that povidone-iodine solution can enhance angiogenesis as a toxicity paradox when used for leg ulcers.<sup>5</sup> The concepts of angiogenesis enhancement and osteoblast differentiation could be beneficial for bone healing and fusion.

In the current study, osteogenesis and fusion rates were not affected by 3.35% povidone-iodine solution; basically osteoblast and osteoprogenitor cellular exposure to iodine needs decortication that was done only after povidone-iodine irrigation. There was only one clinical study commented on the effect of povidone-iodine solution on spinal fusion; they used povidone-iodine solution 0.35% concentration and found that this concentration can be used safely in spine surgeries, with no influence on wound healing, bone union, and clinical outcome.<sup>4</sup>

The current study used 3.35% povidone-iodine solution for irrigation with no effect on the fusion rate compared to the saline only irrigated group. To the best of the authors' knowledge, no publication to date has studied the effect of 3.35% concentration of povidone-iodine solution on fusion rates in lumbar fusion surgery. As this is a retrospective study, no a priori power analysis was done, and the study might be underpowered.

## CONCLUSION

Povidone-iodine 3.35% irrigation in lumbar spine fusion surgery is effective in decreasing postoperative infection with no negative influence on the fusion rate or clinical outcome. A larger prospective randomized study with a priori power analysis is advised for more evaluation of the use of 3.35% povidone-iodine solution for wound irrigation of spinal fusion surgeries.

## REFERENCES

1. Akcay E, Ersahin Y, Ozer F, Duransoy YK, Camlar M, Atci I: Neurotoxic effect of povidone-iodine on the rat spine using a laminectomy-durotomy model. *Childs Nerv Syst* 28(12):2071-5, 2012
2. Angelini GD, Lamarra M, Azzu AA: Wound infection following early repeat sternotomy for postoperative bleeding. An experience utilizing intraoperative irrigation with povidone iodine. *J Cardiovasc Surg (Torino)* 31:793-5, 1990
3. Champagne CM, Cooper LF, Offenbacher S: Macrophage cell lines produce osteoinductive signals that include bone morphogenetic protein-2. *Bone* 30(1):26-31, 2002
4. Chang F-Y, Chang M-C, Wang S-T, Yu W-K, Liu C-L and Chen T-H: Can povidone-iodine solution be used safely in a spinal surgery? *Eur Spine* J15: 1005-14, 2006
5. Fumal I, Braham C, Paquet P: The beneficial toxicity paradox of antimicrobials in leg ulcer healing impaired by a polymicrobial flora: a proof-of-concept study. *Dermatology* 204S1:70-4, 2002
6. Galle PC, Homesley HD: Ineffectiveness of povidone-iodine irrigation of abdominal incisions. *Obstetrics and gynecology* 55(6):744-7, 1980
7. Kaysinger KK, Nicholson NC, Ramp WK: Toxic effects of wound irrigation solutions on cultured tibiae and osteoblasts. *J Orthop Trauma* 9(4):303-11, 1995
8. Ko W, Lazenby WD, Zelano JA: Effects of shaving methods and intraoperative irrigation on suppurative mediastinitis after bypass operations. *Ann Thorac Surg* 53:301-5, 1992
9. Lineaweaver W, McMorris S, Soucy D: Cellular and bacterial toxicities of topical antimicrobials. *Plast Reconstr Surg* 75:394-6, 1985
10. Mangram AJ, Horan TC, Pearson ML, Silver LC, Jarvis WR: Guidelines for prevention of surgical site infection, 1999. Center for disease control and prevention (CDC) hospital infection control practices advisory committee. *Am J Infect Control* 27:97-132, 1999
11. Moore K, Thomas A, Harding KG: Iodine released from the wound dressing iodisorb modulates the secretion of cytokines by human macrophages responding to bacterial lipopolysaccharide. *Int J Biochem Cell Bio* 129(1):163-71, 1997
12. Owens CD, Stoessel K: Surgical site infections: epidemiology, microbiology and prevention. *J Hosp Infect* 70(Suppl 2): 3-10, 2008
13. Patel K, Goldenberg B, Schwartz T: Betadine irrigation and post-craniotomy wound infection. *Clin Neurol Neurosurg* 118:49-52, 2014
14. Picada R, Winter RB, Lonstein JE, Denis F, Pinto MR, Smith MD: Postoperative deep wound infection in adults after posterior lumbosacral spine fusion with instrumentation: incidence and management. *J Spinal Disord* 13:42-5, 2000
15. Reimer K, Wichelhaus TA, Schafer V, Rudolph P, Kramer A, Wutzler P: Antimicrobial effectiveness of povidone- iodine and consequences for new application areas. *Dermatology* 204(Suppl 1):114-20, 2002
16. Scherr DD, Dodd TA, Buckingham WW Jr: Prophylactic use of topical antibiotic irrigation in uninfected surgical wounds. *J Bone Joint Surg (Am)* 54A:634-40, 1972
17. Schofferman J, Slosar P, Reynolds J, Goldthwaite N, Koestler M: A prospective randomized comparison of 270 degrees fusions to 360 degrees fusions (circumferential fusions). *Spine (Phila Pa 1976)* 26(10):E207-12, 2001
18. Sindelar WF, Mason GR: Efficacy of povidon-iodine irrigation in prevention of surgical wound infections. *Surg Forum* 28:48-51, 1977
19. Strohecker J, Piotrowski WP, Lametschwandtner A: The intra-operative application of povidone-iodine in neurosurgery. *J Hosp Infect* 6(Suppl A):123-5, 1985



20. Surgical Site Infection (SSI) Event: Center for Disease Control. Available at: <https://www.cdc.gov/nhsn/pdfs/pscmanual/9pscscscurrent.pdf/>;2010 Updated January. [accessed September 4,2017], 2017
21. Ulivieri S, Toninelli S, Petrini C, Giorgio A and Oliveri G: Prevention of post-operative infections in spine surgery by wound irrigation with a solution of povidone–iodine and hydrogen peroxide. Arch Orthop Trauma Sur 131:1203–6, 2011
22. Watt BE, Proudfoot AT, Vale JA: Hydrogen peroxide poisoning. Toxicol Rev 23(1):51-7, 2004
23. Weinstein MA, McCabe JP, Cammisa FP Jr: Postoperative spinal wound infection: a review of 2,391 consecutive index procedures. J Spinal Disord 13:422–6, 2000

## المخلص العربي

### استخدام البوفيدون أيودين 3.35% مقارنة بالمحلول الملحي الطبيعي للإرواء فى جراحات الاندماج القطنى، دراسة استعادية

**البيانات الخلفية:** البوفيدون أيودين هو مطهر واسع المدى وفعال جدا ضد أنواع مختلفة من البكتريا بضمن ذلك البكتريا العنقودية الذهبية المقاومة للميثيسيلين وبعض أنواع المكورات المعوية وهذه الفعالية ناتجة عن الصفات التطهيرية للأيودين.

**الغرض:** لتقييم أثر استخدام الإرواء بالبوفيدون أيودين 3.35% أثناء العملية فى جراحات الاندماج القطنى

**تصميم الدراسة:** دراسة سريرية استعادية

**عينة المرضى:** 93 جراحة اندماج قطنى فى عام 2016 (مجموعة 1) و112 جراحة اندماج قطنى فى عام 2017 (مجموعة 2)

**إجراءات النتائج:** تم مقارنة كلتا المجموعتين بطريقة استعادية بخصوص معدل العدوى ومعدل الاندماج و حرز أوسويستري للعجز

**المرضى والطرق:** مجموعة 1 حصلت على إرواء بالمحلول الملحي الطبيعي ومجموعة 2 حصلت على إرواء بالبوفيدون أيودين 3.35%

**النتائج:** لوحظ وجود حالتى عدوى سطحية وحالتى عدوى عميقة فى مجموعة 1 ولم تلحظ أى عدوى بمجموعة 2. وجدت حالة واحدة لتفسخ كامل للجرح فى احدى حالتى العدوى العميقة. كانت البكتريا المسببة هى البكتريا العنقودية الذهبية المقاومة للميثيسيلين فى حالتين والكلبسيلا الرئوية فى حالة و توليف بين البكتريا العنقودية الذهبية المقاومة للميثيسيلين والبكتريا العنقودية البشرية فى الحالة الاخيرة. كان هناك اختلاف غير هام بين المجموعتين فى معدل الاندماج ولم يكن هناك علاقة خطية بين مدة الجراحة ومعدل الاندماج فى مجموعة 2. كان هناك تحسن هام فى حرز أوسويستري للعجز بعد العملية فى المجموعتين مقارنة بالحرز قبل العملية، لم يكن هناك اختلاف هام بين المجموعتين عند مقارنة التحسن.

**الاستنتاج:** الإرواء بالبوفيدون أيودين 3.35% فى جراحات الاندماج القطنى فعال فى انقاص معدل العدوى ما بعد العملية مع عدم وجود تأثير سلبى على معدل الاندماج او النتيجة السريرية