

# High Density Pedicle Screws through Posterior Only Approach for Surgical Correction of Severe Adolescent Idiopathic Scoliosis > 70°

Belal Elnady MD, Mohammad El-Sharkawi MD, Mohamed El-Meshtawy MD, Faisal F Adam MD, Khaled M Hassan MD.

*Department of Orthopedic and Trauma surgery, Assiut University Medical School, Assiut, Egypt.*

## Abstract

**Background Data:** The classic treatment of severe rigid adolescent idiopathic scoliosis (AIS) was performed by combined anterior and posterior surgery which carries higher morbidity to the patient. Recently, posterior only surgery using all pedicle screws has been used for treatment of severe AIS with many advantages over combined approaches.

**Purpose:** To evaluate the safety and effectiveness of high density pedicle screws through posterior only approach in correction of severe cases of adolescent idiopathic scoliosis (AIS) with curves > 70°.

**Study Design:** Prospective cohort study.

**Patients and Methods:** Between 2012 and 2014, fourteen patients were surgically treated for severe AIS with curves > 70° and were prospectively followed up for a minimum of 1 year (Range 1-4 years). Clinical outcomes were evaluated using SRS-22 questionnaire. All patients were classified according to Lenke et al classification. Major and minor curves Cobb angle as well as sagittal parameters were measured on whole spine X-rays. Side bending films were used to assess curve flexibility. High density pedicle screws and multiple Ponte osteotomies were used in all patients. Five patients required asymmetrical pedicle subtraction osteotomy due to very rigid curve.

**Results:** This study included 14 patients (8 females, 6 males). The mean age at time of surgery was 17.4 years (range 14-24 years). The mean correction rate for the coronal Cobb angle of the major and minor curves was 73.7% (80.4° preoperative and 21.7° postoperative) and 68.7% (51.5° preoperative and 19.63° postoperative)

Received at:

December 18<sup>th</sup>, 2014

Accepted at:

June 17<sup>th</sup>, 2015

respectively. The mean thoracic kyphosis angle was 44.2° preoperatively, 28.55° postoperatively and 28.1° at latest follow up. The mean SRS-22 questionnaire scores improved significantly from 2.8 preoperatively to 3.7 at the final follow up ( $P > 0.001$ ). No cases of pseudarthrosis, metal failure or neurological deficits were encountered. One patient with asymmetrical PSO developed hemothorax that was managed with chest tube insertion and follow up.

**Conclusion:** High density pedicle screws through posterior only approach is a safe and effective method in treatment of severe AIS. It can achieve coronal curve correction comparable to combined anterior and posterior approaches without the morbidity of combined approaches. It also restores the sagittal profile leading to good functional outcomes and better quality of life. (2014ESJ073)

**Keywords:** High density pedicle screws, severe idiopathic scoliosis, posterior approach, Adolescent spine deformity.

## Introduction

The classic treatment of severe rigid adolescent idiopathic scoliosis (AIS) was performed by an anterior release with an open thoracotomy followed by posterior instrumented fusion.<sup>8</sup> The combined anterior and posterior procedure can be performed in one or two stage surgery with or without halo traction in-between.<sup>2,26</sup> Additional anterior surgery requires increased time for the general anesthesia and may have a negative impact on pulmonary function, longer hospital stay, more blood loss and longer operative time.<sup>5</sup>

Video assisted thoracoscopic surgery (VATS), used for the anterior release, followed by posterior instrumentation have been also used for severe rigid AIS.<sup>6,19</sup> However, it can minimize, but not eliminate, the negative effect on the pulmonary function, as reported by Newton et al,<sup>18</sup>

Pedicle screws, by allowing secure segmental three-column fixation through the familiar posterior approach, have become the principle method for scoliosis correction with many advantages over other fixation method.<sup>24</sup>

The aim of this study was to evaluate the efficacy and safety of using high density pedicle screws through posterior only approach to correct severe cases of AIS with curves  $> 70^\circ$ .

## Patients and Methods

Between 2012 and 2014, fourteen patients with severe AIS were treated surgically and were prospectively followed up for a minimum of 1 year. This study was approved by our institution ethical committee and an informed consent was taken from every patient.

All patients with AIS older than 10 years of age with curves more than  $70^\circ$  were included. Patients with non-idiopathic curves, previous surgery, patients younger than 10 years old as well as those with moderate curves (less than  $70^\circ$ ) were excluded.

After complete medical history and careful physical/neurological examinations, all patients had preoperative whole spine anteroposterior (AP) including the shoulders and the pelvis and lateral films. Side bending films were obtained for all patients to assess curve flexibility.

In the AP view, Cobb angle<sup>7</sup> of the major curves as well as the minor curves was measured. Global coronal balance was measured as the distance between the C7 plumb line and the central sacral vertical line (CSVL). In the lateral view, thoracic kyphosis was measured from the upper end plate of D5 to the lower end plate of D12 and lumbar lordosis was measured from the upper end plate of L1 to the upper end plate of S1. Global sagittal balance was assessed from the distance between C7 plumb line and the posterosuperior corner of S1 in millimeters with positive values in front and negative values behind the posterosuperior corner of S1. In the side bending films Cobb angle of the major and minor curves was measured to assess flexibility of the curves.<sup>21</sup>

All patients were classified according to the Lenke et al. classification<sup>16</sup> into one of the six main types. Lumbar and thoracic sagittal modifiers were determined for every patient and only structural curves were fused.

The upper instrumented vertebra was D4 if the patient had high right shoulder, D3 if the patient had balanced shoulders and D2 if the left shoulder is high. The Lower instrumented vertebra was the end

vertebra if it was touched by the CSVL and End+1 or End+2 if the end vertebra was not touched by CSVL.

### **Surgical Technique:**

All patients were operated in prone position on a transparent surgical table under general anesthesia. High density pedicle screws were inserted across the instrumented levels using the free hand technique. Extended head screws were used as a routine on concave side to assist in apical reduction. After finishing pedicle screws insertion, their optimal position was checked using intraoperative fluoroscopy both in AP and lateral views. Multiple Ponte osteotomies were routinely done to improve curve flexibility. Asymmetrical pedicle subtraction osteotomy (PSO) was done in selected cases with very rigid curve. Concave rod was inserted first and then derotation of the spine was done by rod derotation technique. Insertion of the convex rod and final segmental compression and distraction was used to improve correction.

The wake-up test was used in every patient to ensure neural integrity. Posterior spinal arthrodesis was then done using autologous local bone graft. In this series, no iliac bone graft was used, no local antibiotics were added to the bone graft. Finally, the wound was closed in layers over a suction drain.

All patients were mobilized as early as tolerated without any external support. Post-operative radiograph was taken shortly after surgery and patients were followed up at 2 months, 6 months, 1 year and 2 years after surgery. The preoperative radiological parameters were re-measured shortly after surgery and at each follow up radiograph. Functional outcome was assessed using the SRS-22 questionnaire. Statistical analysis was done using the SPSS program (IBM SPSS version 20.0) using chi-square and t-test. P value less than 0.05 is considered statistically significant.

## **Results**

This study included 14 patients, 8 females and 6 males. The mean age at surgery was 17.4 years (Range 14-24 years). The mean follow up period was 19.6 months (Range 12-44 months). The mean operative time was 354 minutes (Range 280-440 minutes) with mean blood loss of 1400 cc (Range 700-1900 cc) and average 4 units (Range 3 to 6 units) of blood transfusion were needed. The

average number of fusion levels was 15.4 levels with a mean of 23.4 pedicle screws inserted per patient with total 328 screws inserted in 215 levels. Multiple Ponte osteotomies were done in every patient while asymmetrical PSO was done in 5 patients.

The most common curve type was type 3 in 6 patients followed by type 1 in 5 patients (Figure 1). Thoracic kyphosis was normal in 5 patients (Sagittal modifier N), hypokyphosis in 1 patients (Sagittal modifier -) and hyperkyphosis (Figure 2) in 8 patients (Sagittal modifier +).

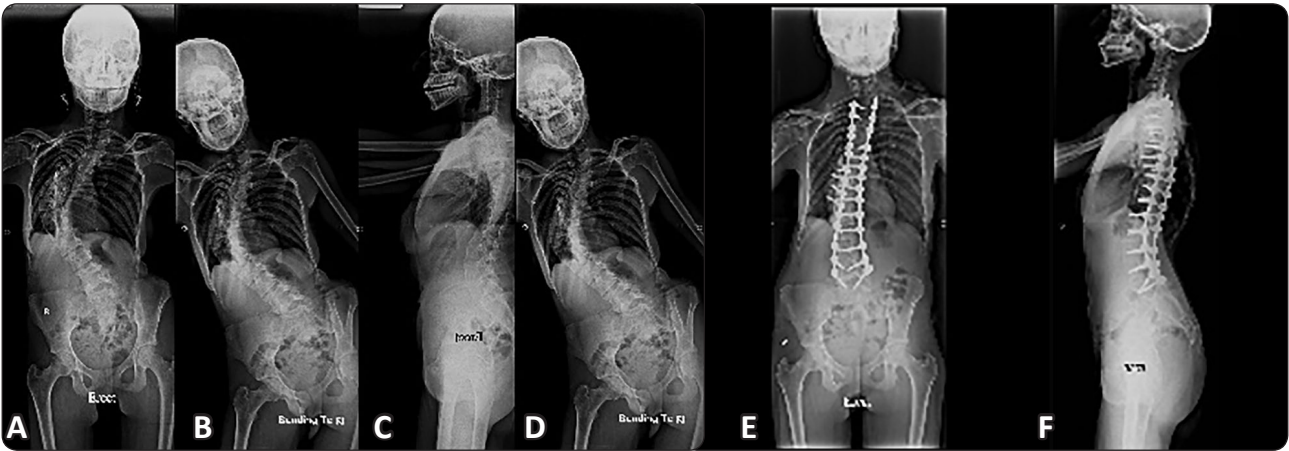
The mean preoperative Cobb angle of the major curve was 80.4° with a mean of 19.7% curve flexibility (Figure 3). This had been corrected to 21.07° postoperative (P<0.001) and to 22.2° at latest follow up. The percent of curve correction was 73.7% with 1.9% loss of correction at latest follow up (P=0.796).

The mean cobb angle of the minor curve was 51.5° preoperative (Figure 3), that has been corrected to a mean of 19.4° postoperative (P<0.001) and was 20.86° at latest follow up with 68.7% percentage correction of the minor curve and 2.4% percentage loss of correction at latest follow up (P=0.436). The mean global coronal balance was 2.89 cm preoperatively, 1.76 cm postoperatively (P=0.047) and 0.9 cm at latest follow up (P=0.112).

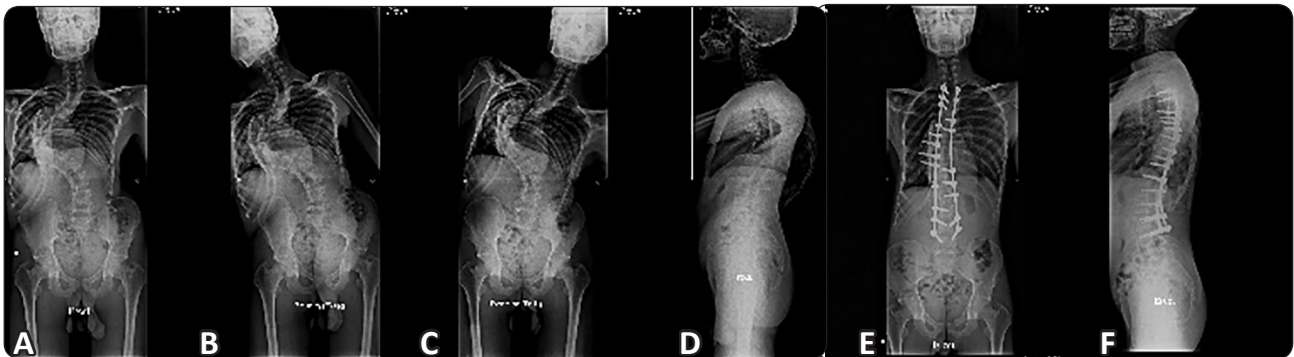The mean preoperative thoracic kyphosis (Figure 4) was 44.2° and was 28.5° postoperatively (P=0.003). At the latest follow up the mean thoracic kyphosis was 28.1° (P=0.789). The mean lumbar lordosis was 50.1° preoperatively, 41.0° postoperatively (P=0.016) and 42.2° at latest follow up (P=0.865). The mean global sagittal balance was -25 mm preoperatively and +37 mm (P=0.971) postoperatively and +26 mm at latest follow up (P=0.688).

The SRS 22 questionnaire improved significantly from a mean of 2.8 preoperative to 3.7 at latest follow up (P<0.001). Both the total score and the 5 domains scores improved after surgery.

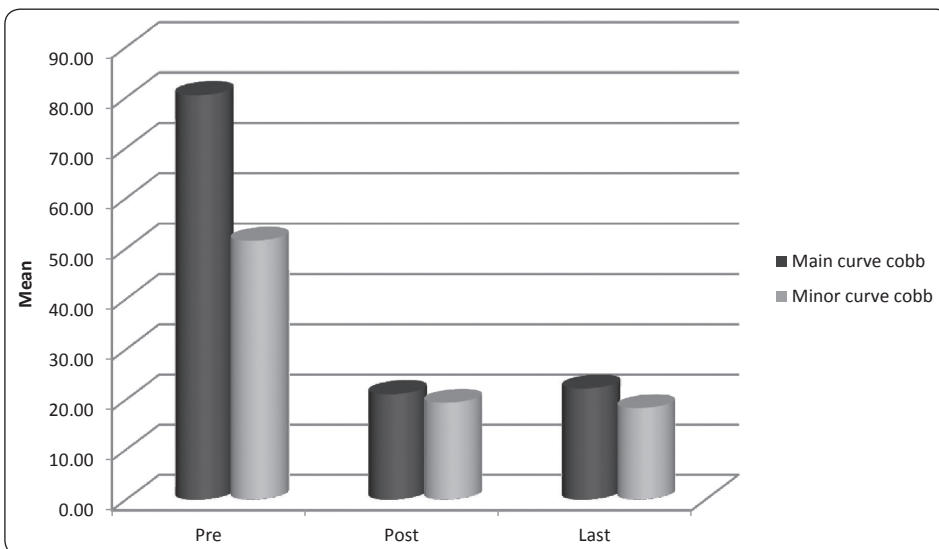
In this series, there were no cases with neurological deficits post-operatively. No metal failure or pseudarthrosis was detected during the follow up period. One patient with asymmetrical PSO developed hemothorax postoperatively that was managed with chest tube insertion for 24 hours.



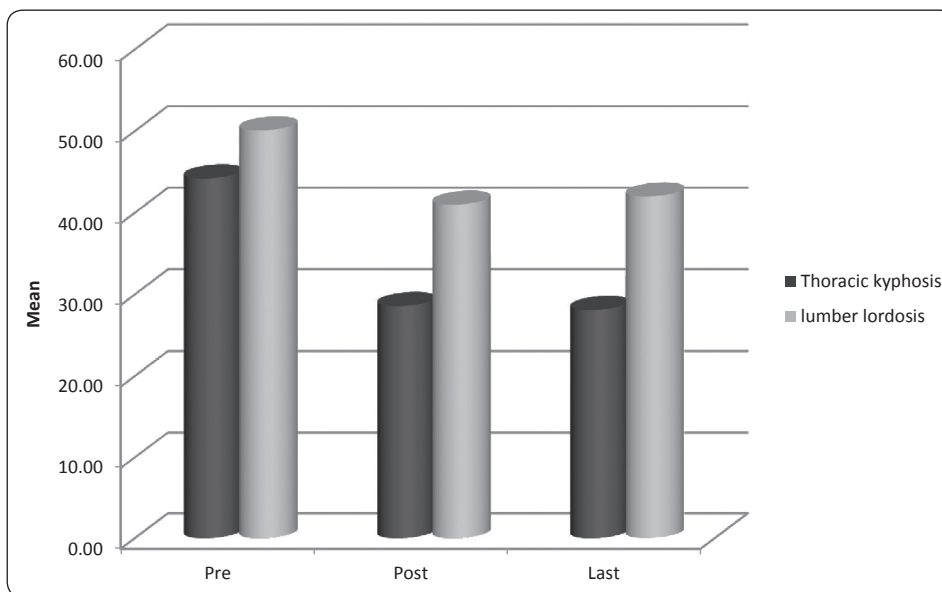
**Figure 1.** (A-D) whole spine X-ray: Preoperative AP, Rt bending, Lat, Lt bending views of male patient 16 years old with Lenke 1 c n, showing main thoracic curve of 85° that had been corrected to 80° in side bending films with thoracic kyphosis of 40° and postoperative. (E,F) Two years postoperative showing posterior instrumentation from D3-L5 with main thoracic curve correction to 22° with thoracic kyphosis of 28°.



**Figure 2.** (A-D) whole spine preoperative X-rays AP, Rt bending, Lt bending, Lat views of male patient 18 years old with Lenke 4 a +, showing main thoracic curve of 105° with thoracic kyphosis of 52°. (E,F) One and half year postoperative whole spine X-rays showing posterior fusion from D2-L4 with main thoracic curve correction to 44° with thoracic kyphosis of 32°.



**Figure 3.** Coronal parameters.



**Figure 4.** Sagittal parameters.

## Discussion

In recent years, posterior only surgery using all pedicle screws has been used for treatment of severe AIS and has resulted in similar correction rate to the combined anterior/posterior approach with much less morbidity than the combined approaches.<sup>11,15,17</sup> In this prospective cohort study, we have achieved 73.7% coronal correction of the major curve which is better than previous studies using posterior only approach for severe AIS which ranged from 52% to 68%.<sup>1,3,4,8,9,15,23</sup> We think that increasing implant density as well as using extended head reduction screws on concave side in our patients offered an efficient derotation maneuver and this may have resulted in better curve correction. Also, the routine Ponte osteotomies in all patients and asymmetrical PSO in very rigid curves improved curve correction and may also explain the better coronal correction in this study.

Regarding the sagittal profile, the mean final thoracic kyphosis in this series is 28.7° and the mean lumbar lordosis is 42.2°. This falls within the normal range of thoracic kyphosis and lumbar lordosis and indicates the ability of all pedicle screws through posterior approach to keep sagittal parameters. Dobbs et al,<sup>11</sup> found similar correction rate between combined anterior/posterior fusion and posterior only fusion in curves exceeding 90° with less

negative effect on pulmonary function in posterior only group.

Luhmann et al,<sup>17</sup> also concluded that correction achieved by posterior pedicle screws only is similar to combined approach in severe curves (70-100)° and avoided the negative effect of anterior release on pulmonary function. Similar results came from Kuklo et al,<sup>15</sup> in curves more than 90°. These studies concluded that isolated posterior correction with pedicle screws can result in satisfactory correction without the morbidity of anterior release and motivated many authors to state that anterior release is no longer mandatory in severe rigid curves of AIS.

The posterior approach for scoliosis correction is a simple exposure, familiar to all surgeons, with little risk for major vascular injury and with good control of the coronal and sagittal plane of the spine. Also, it preserves the pulmonary function as the chest cage is not violated under normal circumstances.<sup>13</sup>

Pedicle screws related complications can result from initial malposition of the screws or due to screws pull out during deformity correction resulting in neurological, vascular or visceral injury as well as loss of correction in the postoperative period. Despite the high rate of screw misplacement that can reach up to (15.7%) in some studies,<sup>10</sup> the incidence of major complication requiring revision surgery is very low<sup>12,20</sup> and have been reported as

single case reports.<sup>22</sup> Several techniques have been used to guarantee safety of thoracic pedicle screws. These include the anatomical free hand technique<sup>14</sup> as well as the open lamina technique<sup>25</sup> with direct visualization of the medial wall of the pedicle. In this series we used the free hand anatomical technique and we have no screws related major complication that required revision surgery out of 328 screws used.

In 2015, Chen and Rong,<sup>5</sup> published a meta-analysis comparing combined anterior–posterior approach versus posterior-only approach in treating AIS. They concluded that posterior-only approach can achieve similar coronal plane correction compared to combined anterior–posterior approach with better sagittal correction in severe AIS patients. They reported significantly less complication rate, blood loss, operative time, length of hospital stay and better percent-predicted FVC by posterior-only approach.

## Conclusion

High density pedicle screws technique through posterior only approach is an effective and safe method for treatment of severe AIS. It alleviates the need for anterior surgery and eliminates combined approaches related morbidity. It can achieve similar curve correction with minimal loss of correction. It also restores the sagittal parameters within normal range leading to better sagittal balance. The screw related complications are minimal and major complications rarely occur. As the incidence of severe AIS is relatively uncommon, we recommend performing this study as a multicenter study to include large number of patients with longer follow up periods.

## References

1. Arlet V, Jiang L, Quellet J: Is there a need for anterior release for 70–90° thoracic curves in adolescent scoliosis? *European Spine Journal* 13(8):740-5, 2004
2. Bullmann V, Halm HF, Schulte T, Lerner T, Weber TP, Liljenqvist UR: Combined anterior and posterior instrumentation in severe and rigid idiopathic scoliosis. *European Spine Journal* 15(4):440-8, 2006
3. Burton DC, Sama AA, Asher MA, Burke SW, Boachie-Adjei O, Huang RC, et al: The treatment of large (> 70°) thoracic idiopathic scoliosis curves with posterior instrumentation and arthrodesis: When is anterior release indicated? *Spine* 30(17):1979-84, 2005
4. Chang K-W: Cantilever bending technique for treatment of large and rigid scoliosis. *Spine* 28(21):2452-8, 2003
5. Chen Z, Rong L: Comparison of combined anterior–posterior approach versus posterior-only approach in treating adolescent idiopathic scoliosis: a meta-analysis. *European Spine Journal* :1-9, 2015
6. Cheung KM WJ, Cheng QH, Ma BS, Gao JC, Luk KD: Treatment of stiff thoracic scoliosis by thoracoscopic anterior release combined with posterior instrumentation and fusion. *J Orthop Surg Res* 2-16, 2007
7. Cobb J. Outline for the study of scoliosis. *Instr Course Lect* 5:261-75, 1948
8. Crostelli M, Mazza O, Mariani M, Mascello D: Treatment of severe scoliosis with posterior-only approach arthrodesis and all-pedicle screw instrumentation. *European Spine Journal* 22(6):808-14, 2013
9. Di Silvestre M, Bakaloudis G, Lolli F, Vommaro F, Martikos K, Parisini P: Posterior fusion only for thoracic adolescent idiopathic scoliosis of more than 80: pedicle screws versus hybrid instrumentation. *European Spine Journal* 17(10):1336-49, 2008
10. Di Silvestre M, Parisini P, Lolli F, Bakaloudis G: Complications of thoracic pedicle screws in scoliosis treatment. *Spine* 32(15):1655-61, 2007
11. Dobbs MB, Lenke LG, Kim YJ, Luhmann SJ, Bridwell KH: Anterior/posterior spinal instrumentation versus posterior instrumentation alone for the treatment of adolescent idiopathic scoliotic curves more than 90. *Spine* 31(20):2386-91, 2006
12. Gertzbein SD, ROBBINS SE: Accuracy of pedicular screw placement in vivo. *Spine* 15(1):11-4, 1990
13. Kim YJ, Lenke LG, Bridwell KH, Cheh G, Whorton J, Sides B: Prospective pulmonary function comparison following posterior segmental spinal instrumentation and fusion of adolescent

- idiopathic scoliosis: is there a relationship between major thoracic curve correction and pulmonary function test improvement? *Spine* 32(24):2685-93, 2007
14. Kim YJ, Lenke LG, Bridwell KH, Cho YS, Riew KD: Free hand pedicle screw placement in the thoracic spine: is it safe? *Spine* 29(3):333-42, 2004
  15. Kuklo TR, Lenke LG, O'Brien MF, Lehman Jr RA, Polly Jr DW, Schroeder TM: Accuracy and efficacy of thoracic pedicle screws in curves more than 90. *Spine* 30(2):222-6, 2005
  16. Lenke LG, Edwards CC, Bridwell KH: The Lenke classification of adolescent idiopathic scoliosis: how it organizes curve patterns as a template to perform selective fusions of the spine. *Spine* 8(20S):S199-S207, 2003
  17. Luhmann SJ, Lenke LG, Kim YJ, Bridwell KH, Schootman M: Thoracic adolescent idiopathic scoliosis curves between 70° and 100°: Is anterior release necessary? *Spine* 30(18):2061-7, 2005
  18. Newton PO, Marks M, Faro F, Betz R, Clements D, Haher T, et al: Use of video-assisted thoracoscopic surgery to reduce perioperative morbidity in scoliosis surgery. *Spine* 28(20S):S249-S54, 2003
  19. Niemeyer T, Freeman B, Grevitt M, Webb J: Anterior thoracoscopic surgery followed by posterior instrumentation and fusion in spinal deformity. *European Spine Journal* 9(6):499-504, 2000
  20. Smorgick Y, Millgram MA, Anekstein Y, Floman Y, Mirovsky Y: Accuracy and safety of thoracic pedicle screw placement in spinal deformities. *Journal of spinal disorders & techniques* 18(6):522-6, 2005
  21. Studer D: Clinical investigation and imaging. *Journal of children's orthopaedics* 7(1):29-35, 2013
  22. Sud A, Tsirikos AI: Current concepts and controversies on adolescent idiopathic scoliosis: Part I. *Indian journal of orthopaedics* 47(2):117, 2013
  23. Suk S-I, Kim J-H, Cho K-J, Kim S-S, Lee J-J, Han Y-T: Is anterior release necessary in severe scoliosis treated by posterior segmental pedicle screw fixation? *European Spine Journal* 16(9):1359-65, 2007
  24. Suk S-I, Kim W-J, Lee S-M, Kim J-H, Chung E-R: Thoracic pedicle screw fixation in spinal deformities: are they really safe? *Spine* 26(18):2049-57, 2001
  25. Xu R, Ebraheim NA, Ou Y, Yeasting RA: Anatomic Considerations of Pedicle Screw Placement in the Thoracic Spine: Roy-Camille Technique Versus Open-Lamina Technique. *Spine* 23(9):1065-8, 1998
  26. Yamin S, Li L, Xing W, Tianjun G, Yupeng Z: Staged surgical treatment for severe and rigid scoliosis. *Journal of orthopaedic surgery and research* 3(1):26, 2008

Address reprint  
request to:

**Belal Elnady MD.**

Orthopedic Surgery, Assiut University Medical School, Assiut, Egypt  
Email: belalelnady83@gmail.com

## الملخص العربي

### الإصلاح الجراحي لجنف العمود الفقري الشديد بالمراهقين في جلسة واحدة من الخلف باستخدام كثافة عالية من مسامير جذور الفقرات

**البيانات الخلفية:** تعتبر الحالات الشديدة من اعوجاج العمود الفقري في المراهقين من المعضلات الجراحية. وكان إصلاح هذه الحالات يحتاج إلى إجراء جراحة من الأمام ثم من الخلف حتى يتم إصلاح مثل هذه الحالات بشكل مرضي. وقد يتم عمل الجراحتين من الأمام والخلف في جلسة تخدير واحدة مما يمثل حملاً كبيراً على المريض من حيث التعرض لمدة أطول من التخدير وفقدان كمية أكبر من الدماء ويمكن أن يكون لها تأثير سلبي على وظائف الرئة مما يتطلب وقتاً أطول للمريض لاستعادة عافيته. وقد يتم عمل الجراحتين في جلسيتين مختلفتين بينهما فاصل زمني مختلف مع عمل شد للفقرات بين الجراحتين. ومع التقدم الكبير في الوسائل الجراحية وأنواع المسامير المستخدمة في إصلاح مثل هذه الحالات أصبح من الممكن إصلاح مثل هذه الحالات من الخلف فقط في جلسة جراحية واحدة باستخدام مسامير عنق الفقرة مما يوفر على المريض التعرض لجراحه أخرى من الأمام.

**الهدف:** هدف هذا البحث هو تقييم مدى فاعلية وأمان إجراء مثل هذه الجراحات من الخلف فقط في جلسة واحدة باستخدام كثافة عالية من مسامير عنق الفقرة.

**الطرق والمرضي:** وقد تم عمل دراسة مستقبلية لأربعة عشر مريضاً يعانون من اعوجاج شديد في العمود الفقري لأكثر من سبعين درجة وتمت متابعة هذه الحالات لمدة لا تقل عن عام بعد إجراء الجراحة وقياس معدل تصليح الاعوجاج بعد الجراحة والمضاعفات الناتجة عن مثل هذه الجراحات.

**النتائج:** وأظهرت نتائج هذه الدراسة مدى فاعلية هذه الطريقة في إصلاح الحالات الشديدة من اعوجاج العمود الفقري في المراهقين بنسبة تصليح تجاوزت ٧٣% بدون حدوث مضاعفات كبرى في أي من المرضى وهذه النسبة تماثل نسب التصليح المتحققة من الدراسات السابقة لعلاج مثل هذه الحالات على مرحلتين من الأمام والخلف ولكن بدون الحاجة لجراحه أخرى من الأمام مما يقلل من المضاعفات الناتجة عن هذه الجراحة بشكل كبير.