

The Role of Long Segment Posterior Fixation and Transpedicular Decompression in the Management of Thoracolumbar Fractures

Mohamed Elgohary MD., Saudi Zamzam MD., Mohamed Okasha, MD.

Neurosurgery Department, Damanhour Medical National Institute, Damanhour, Egypt.

Abstract

Background Data: Treatment of spinal injury aims for restoration of spinal anatomy, relieving the pain and achieving stability without neurological damage. One of the recent surgical approaches to spinal cord compression is transpedicular re-impaction of retro-pulsed vertebral body fragments and/or partial or complete corpectomy with vertebroplasty and posterior fixation.

Purpose: to assess the effectiveness of the transpedicular approach in spinal decompression, reconstruction, realignment and fixation.

Study design: prospective clinical case study.

Patient and Methods: we report on 25 patients with traumatic dorso-lumbar fracture causing anterior neural compression. Ten patients were males and 15 were females. The mean age was 39.4 ± 16.8 (range 17-60). Outcome measures: clinical outcome was assessed by visual analogue scale for pain and ASIA-Imso scale for motor. Radiological outcome assessed canal compression, vertebral height and kyphotic angel. All patients had been operated posteriorly, with transpedicular decompression with and without vertebroplasty. Long segment pedicle screw fixation was done in all cases. Follow up period was 12 months.

Results: Significant improvement in pain and motor state was recorded in early postoperative scales that maintained in late postoperative scale. Canal compromise, vertebral height and kyphotic angel were significantly reduced.

Conclusion: Transpedicular approach is an effective technique done in familiar position. It is a safe, taking relatively short time, with minimal blood loss and with few operative complications. The procedure achieved significant ventral decompression, improved and maintained vertebral alignment. (2013ESJ048)

Key words: Dorso-lumbar fracture, Transpedicular approach, vertebroplasty, long segment, pedicle screw fixation

Introduction

Stability of the vertebral column is supplied by the vertebral muscles, the ligaments, the inter-vertebral discs and the curvatures. The most important factors are the size of the inter-vertebral disc in relation to the bony segments and the direction in which the articular facets face. Instability, or loss of stability, is a pathological process which leads to displacement of vertebrae behind their normal physiological limits.¹⁵

Controversy is still unresolved as to which technique of surgery is best for injuries of the thoracic and lumbar spine, and there is still no consensus between surgical centers and rehabilitation centers as to whether surgery is indicated at all, and in which cases it should be used.²

The goal of treating any injury is to restore anatomy and function of the injured part as completely as possible. The aim of spinal injury treatment is the restoration of spinal physiology, with relief of pain and restoration of stability without neurological damage.⁵

Indications of surgery in fracture spine included: dislocations and fracture dislocations, large defect in the vertebral body anteriorly, the deformity remaining after healing has occurred may lead to long term symptoms due to the resulting kyphosis, that automatically results in a major incongruity of the intervertebral joints, leading to spondyloarthrosis.⁸

For many years, surgical measures were restricted to laminectomy, but recently decompression of the spinal cord through transpedicular re-impaction of retropulsed body fragments had been experienced. The aim of this study was to assess the effectiveness, advantages and disadvantage of transpedicular approach in management of dorso-lumbar fractures.

Patients and Methods

This study was conducted during the period from October 2009 to March 2012. Twenty five patients including 10 males and 15 female with mean age 39.4 ± 16.8 (range 17-60 years) were recruited for this study. We included patients who sustained traumatic thoraco-lumbar burst fractures type A and B according to Magerl's classification.¹² All patients were admitted and managed at the Neurosurgery Department, Damansara National Institute.

All patients had preoperative full clinical and radiological assessment. Clinical assessment included full neurological examination including

pain evaluation with the Visual Analogue Scale¹, and evaluation of the motor state according to ASIA-Imsoop scale.¹⁴ Radiological evaluation included Plain X-Ray, Multi-slice 3-D CT-Scan, and MRI to identify the type of fracture, canal compromise, vertebral height and kyphotic angle. Fractures were classified according to Magerl's classification.¹² Canal compromise was evaluated by measuring the AP diameter of the injured segment as a percentage of the adjacent segment. Vertebral height was evaluated as a percentage of the adjacent vertebra. Kyphosis was estimated using Cobb's angle procedure.

The procedure was done under general anesthesia in the standard prone position. A midline incision of sufficient length to encompass the posterior implant is selected over the fracture site. Sharp dissection should be employed. The fracture was identified and confirmed by a fluoroscopic imaging. The transpedicular approach to the fractured body commenced by careful identification and dissection of the intended pedicle/s. Entry through the intended pedicle was performed by high speed drill. Whether the right or left pedicle is drilled based on the configuration of the fracture as determined by the preoperative CT scan. Removal of the medial wall of the pedicle to identify the thecal sac in the spinal canal was performed. The compressing elements (fractured retro-pulsed fragment, hematoma or intervertebral disc) were identified. The bony retro-pulsed fragment was either reducible which was re-impacted, or if not, the posterior portion of vertebral body was then removed to give space for fragment to be impacted. The remaining rim of bone is then fractured into the cavity with a thin impactor and is removed with pituitary rongeurs. If complete decompression is not obtained through one pedicle, the procedure is repeated from the contralateral side. Leaving a thin rim of bone to protect the dural content till adequate decompression is crucial.

In cases in which incomplete corpectomy had been done, vertebroplasty and grafting has been done by bone cement through the pedicle (Figure 1). In cases of vertebroplasty with bone cement, bilateral pediculotomy was important for monitoring of the injected cement, one pedicle for injection and through the other pedicle dura was protected by dissectors and a double layer of gel foam anterior to the dura. Long segment posterior instrumentation

by transpedicular screws (polyaxial top loading system) with or without posterolateral bone fusion was done. The wound was closed in layers in usual method after drains are placed (Figure 2,3).

Results

The age of the patients included in the present study ranged between 17-60 years with a mean of 39.4 ± 16.8 years. The most common age group was 30-40 years. The present study included 15 females (60%) and 10 males (40%). The duration of surgery ranged from 2-5 hours with the mean of 3.25 hours. Associated diseases like Hypertension was reported in 5, bronchial asthma in 4, Coronary artery disease in 2, and Diabetes in 4 patients.

According to visual analogue pain scale the pain ranged from 60 to 90 with a mean of 75.2. The preoperative motor power according to ASIA-Imsop scale was grade A in none, grade B in 2, grade C in 4, grade D in 8 and grade E in 11 patients. Types of burst fracture included type B burst fractures (N=18) (upper end plate fracture) were more common than type A burst fracture (N=7) (upper and lower end plates fracture) among all studied patients. The canal compression percent ranged between 25-80% with the mean of 66.8. Vertebral height percent

ranged from 20-70% with the mean of the 36.80. Kyphotic angle ranged from 15-30 with the mean of 22.85. The blood loss ranged from 300-800 cc with the mean of 504 cc. The duration of the hospital stay ranged from 5-10 days with the mean of 7 days.

According to the visual analog scale, postoperatively pain improved from 75.2 (60-90) to 9.78 (5-20), and that was statistically significant ($P=0.00001$). Motor power according to ASIA/Imsop scale showed a statistically significant improvement in motor state between preoperative and postoperative ($P=0.0001$) (Table 1). The percentage of canal compression was significantly decreased in post-operative in the studied group. The AP compromise improved from 66.2 (25-80) to 9.88 (0-35), $P=0.001$. There was a significant increase in percentage of the vertebral height between pre- and post-operative (one year). The height improved from 36.8 (20-70) to 78.64 (40-95), $P=0.0001$. Kyphotic angle was significantly decreased in post-operative from the preoperative angle. The angle improved from 22.58 (15-30) to 12.83 (10-18), ($P=0.001$) (Table 2).

Reported morbidity included wound infection in one and CSF leakage in 2 patients. There were no reports of neurological deterioration.

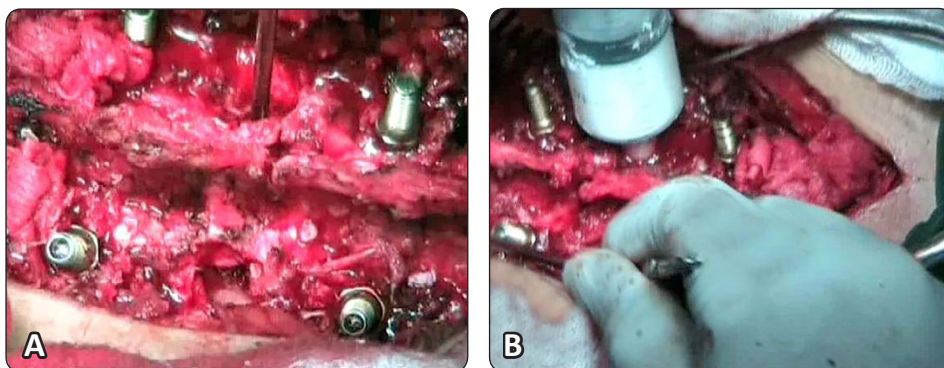
Table 1. Evaluation of Motor Grading

Preoperative		Postoperative			
		B	C	D	E
B	2	0	1	1	0
C	4	0	0	1	3
D	8	0	0	1	7
E	11	0	0	0	11
Total		0	1	3	21
P		0.0001			

Table 2. Radiological Outcome Parameters

Parameters	Pre operative	Post operative	P Value
Canal compression (%)	66.2 (25-80)	9.88 (0-35)	0.001
Vertebral height (%)	36.8 (20-70)	78.64 (40-95)	0.0001
Kyphotic angle	22.58 (15-30)	12.83 (10-18)	0.001

Figure 1. (A) Operative image showing the transpedicle decompression procedure, (B) Vertebral reconstruction under vision with bone cement injection.



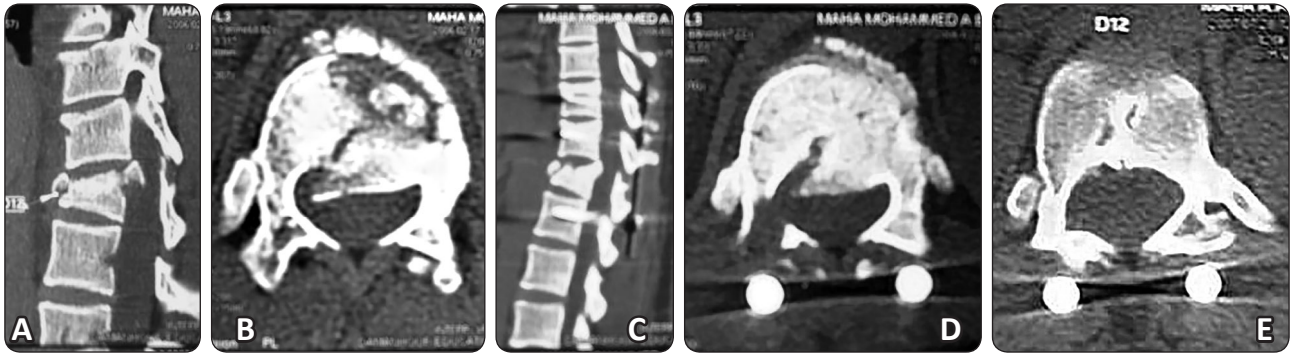


Figure 2. Pre operative CT spine (A) sagittal and (B) axial plan showing DV12 type B burst feature, postoperative (C) sagittal and (D) axial CT spine showing adequate decompression, (E) Late postoperative axial CT spine showing bone remodeling.

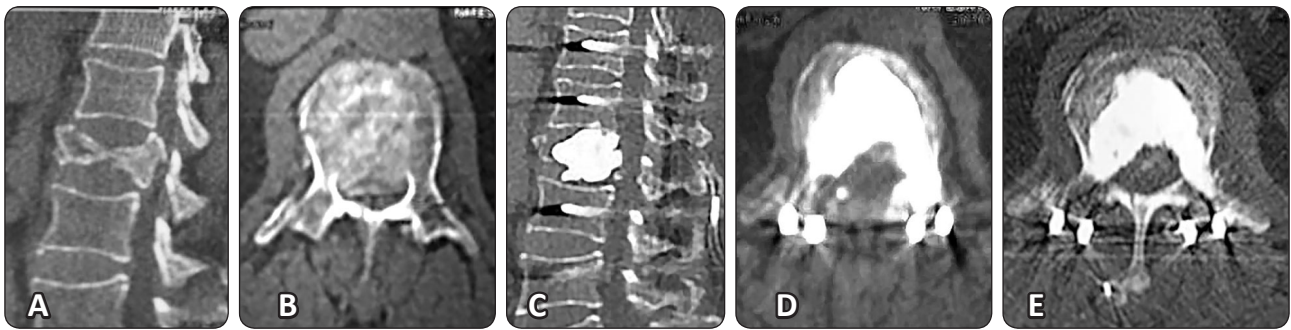


Figure 3. (A) Pre operative CT spine sagittal plan showing L1 Type A burst feature, (B) CT spine axial plan showing severe canal compression, (C) Sagittal CT spine showing posterior decompression with long segment fixation and bone cement reconstruction, (D) Axial CT spine showing partial decompression of the canal, (E) Late postoperative axial CT spine showing remodeling of the canal

Discussion

Transpedicular screw fixation is the only method for stabilizing the three columns fractures and this agrees with Vaccaro et al,¹⁸ who concluded that, in the presence of three columns injury a reteroperitoneal approach cannot provide adequate stabilization and necessitating both ventral and dorsal stabilization. Shaker and Votey¹⁶ have mentioned that in a burst fracture with retero-pulsed bone in the canal, adequate decompression of the canal can be performed by using the transpedicular approach, this can be performed unilaterally or bilaterally, a conclusion that had confirmed our results.

Transpedicular approach is a simple technique allowing true decompression and reconstruction of the vertebral body with less blood loss and shorter duration than thoraco-abdominal approach.^{4,9}

In the present study the operative time was

short and with less blood loss and this agrees with the series of Cotter TM.⁷ In their series they included 22 patients with thoracolumbar fractures operated through transpedicular approach. Kim and Fredrickson¹⁰ reported three operative complications, two CSF leakage and one delayed wound infections. While Mark et al,¹³ in their retrospective review of 20 consecutive patients with the same pathology: 2 patients complicated with dural tears and CSF leakage and 2 cases with superficial wound infections.

In our series there were three complications; two cases CSF leak and one deep wound infection that matched with the results of Knop and Fabian¹¹ who operated 76 patients with thoraco-lumbar burst fractures through transpedicular approach. In this study two complications were observed: one iatrogenic vertebral arch fracture and one deep infection. While in their series, Shaker and

Votey¹⁶ reported the complications of surgery were three cases had wound infection, one case had thromboembolic event and one case had pneumonia.

Significant reduction in pain reported in the present series was confirmed with the series of Steven M et al,¹⁷ in a retrospective reviews of 19 patients.

Regarding neurological symptoms, significant improvement was reported in the present study, a result that matches with those reported by Corta et al,⁶ and Xiang et al,¹⁹ in their series of 27 and 30 patients with burst fractures by transpedicular decompression and posterior stabilization regarding the vertebral height. Significant differences were found regarding canal compromise, Kyphotic angle and vertebral height. Similar results were obtained among cases of the present series with significant improvement of the three parameters.

Conclusion

Transpedicular approach with posterior fixation achieved the goals of surgery including short operative time, with minimal blood loss and few operative complications with short hospital stay. All patients improved according to the motor state. Radiologically, the spinal canal was decompressed, vertebral height increased and the kyphotic angel decreased.

References

1. Aitken RCB: Measurement of Feelings Using Visual Analogue Scales. Proc. roy. Soc. Med. (62): 989-993, 1969
2. Bedbrook EM: Treatment of thoraco lumbar dislocation and fracture with paraplegia. Chin Orthop 112:27-34, 1985
3. Bohlman HH, Dejak J: The results of treatment of Acute thoraco lumbar injuries. J Bone Joint Surg Am 90: 360-369, 2002
4. Borrssave A, Rehtin GR: Complications of surgical treatment of Thoraco lumbar burst fractures. New York Raven: 215-222, 2003
5. Braken MB, Shephard MJ, Callins WF: Arandmized, controlled trial of methyleprionsolone in the treatment of acute spinal cord injuries: Results of the Third National Acute spinal cord injury NASCIA. HAMA 277:1597-1604, 1997
6. Corta P, Arino Vel: Our experience in 33 cases of thoraco lumbar fracture. Chir organi Mov 85:167-175, 2006
7. Cotter TM: Introduction to thoraco lumbar fractures. Instruct Course lect 48:427-428, 2004
8. Denis F: Spinal instability as defined by the three-column spine concept in acute spinal trauma. Clinic Orthop 189:65-76, 1984
9. Geregony A, Cotler JM: Thoraco lumbar spine truma: I/II. Principles of management. J. Am Acad Orthop Soc 3:353-560, 2003
10. Kim AA, Fredrickson BE: Thoraco lumbar spine injuries. Orthopedics 20:939-944, 1997
11. Knop C, Fabian HF: Complications of poison in fixation of Thoraco lumbar fractures. Spine 30:88-90, 2004
12. Magerl F, Harms J, Gertzbein SD, Aebi M, Nazarian S: A new classification of spinal fractures. Presented at the Societal Internationale de Chirurgie Orthopddique et de Traumatologie (SICOT) Meeting, Montreal, September 9, 1990
13. Mark H, Brisky M, Winter RB: The treatment of Thoraco and lumbar fractures a study of 123 cases treated surgically Chir Organi Mav 85(2):173-185, 2004
14. Maynard FMJr, Cauins WF: International standards for neurological and functional classification of spinal cord injury. American Spinal Injury Association spinal cord 35:266-274, 1997
15. Modic MT, Hardy RW, Bamphery F: Evaluations of the results of fixation of unstable fractures of lower dorsal and lumbar vertebra using transpedicular screws plates. Neurosurgery 15:583-92, 1984
16. Shaker M, Votey S: Emergency department approach to acute Thoraco lumbar Spine Injury. J Emrg Med 25:49-60, 2006
17. Steven M, Lim TH, Hong HJ: Biomechanical evaluation of anterior and posterior fixation in unstable Thoraco lumbar fractures. Spine 40:261-266, 2004
18. Vaccaro AR, Slot GH: Anterior instrumentation of the spine in thoraco lumbar fractures. Spine 12:734-740, 2000
19. Xiang L, Bormase T: Simultaneous anterior posterior Thoraco lumbar surgery. J Spine Disord 24:378-384, 2007

الملخص العربي

دور تثبيت قطاع طويل خلفي وتخفيف الضغط عبر عنق الفقرة في علاج كسور الفقرات الظهر- قطنية خلفية البيانات: علاج إصابات العمود الفقري تهدف لاستعادة تشريح العمود الفقري، والتخفيف من الألم وتحقيق الاستقرار من دون ضرر للجهاز العصبي. ويعتبر التثبيت الخلفي مع تخفيف الضغط عبر عنق الفقرة من خلال الاستئصال الجزئي أو الكلي للقرص وإعادة تشكيلها أحد الطرق الحديثة في علاج مثل تلك الكسور. الغرض: تقييم مدى كفاءة المدخل الجراحي عبر عنق الفقرة مع التثبيت الخلفي للفقرات في علاج كسور المنطقة الظهر- قطنية

المرضى وطرق العلاج: اشتملت الدراسة على ٢٥ مريضا يعانون كسرا ظهراني قطني مع الضغط الأمامي على النخاع الشوكي. وكان عشرة مرضى من الذكور و ١٥ من الإناث. وكان متوسط العمر 39.4 ± 16.8 (المدى ١٧-٦٠). تم تقييم النتائج السريرية على نطاق التماثلية البصرية للألم ومقياس ASIA-ImSOP. وكذا تقييم ضغط القناة، ارتفاع الفقري والملاك حدابي إشعاعيا. وتم علاج جميع المرضى بالتثبيت الخلفي بمسما عنق الفقرة ، مع إزالة الضغط مع أوبدون حقن الفقرات. وكانت فترة المتابعة ١٢ شهرا.

النتائج: تحسن كبير في الألم والحالة الإكلينيكية وتم تسجيلها في جداول ما بعد الجراحة المبكرة والتي استقرت حتى أواخر نطاق المتابعة. كذلك ظهر تخفيض ملحوظ بعد العملية الجراحية في تسوية القناة و الارتفاع الفقري والتحدب الفقري.

الخلاصة: هذا النهج هو أسلوب فعال وآمن وقصير الوقت نسبيا مع الحد الأدنى من فقدان الدم ومضاعفات قليلة. و حقق الإجراء إزالة الضغط وتحسين والتحدب الفقري.