

# Lumbar disc surgery in pediatric population, Is it a special entity distinct from adult?

Ali Abou-Madawi, MD

Neurosurgical department, Suez Canal University, Ismailia, Egypt

## Abstract

**Background data:** Lumbar disc prolapse is rare in pediatric patients though it may lead to significant pain and disability. Due to different structural properties and environmental and occupational exposures, pediatric LDP may be considered as a separate entity distinct from adult.

**Aim:** This retrospective analytic outcome study was undertaken to determine the clinical outcome and the peculiar characteristics of LDP in pediatric patients.

**Methods:** The medical records of patients younger than 18 years old who were operated for LDP between 1996 and 2011 were reviewed. Patients' preoperative clinical and radiographic data, operative, early and late postoperative data were reviewed.

**Results:** 17 patients were enrolled in this study, 12 males and 5 females. The average age was 15.2 years. The average duration of symptoms was 13.1 months. The average clinical follow-up was 12.1 months. Prior to surgery, all patients had sciatica, 24% had motor deficit, 59% had paresthesia, and 82% had tight hamstring. At the last follow-up, 41% of our patients had excellent, 47% had good, 12% had fair, and none had poor clinical outcome. Regarding the Pain Visual Analogue Scale, back pain reduced from 78.5 to 32.2, and leg pain from 92.1 to 21.3.

**Conclusion:** Lumbar disc surgery in pediatric patients is safe and does not lead to chronic back illness or affect physical activity of patients. It should be considered as a special clinical entity distinct from adult disease  
(2012ESJ002)

**Key words:** lumbar disc, pediatric, outcome, discectomy.

## Introduction

Lumbar disc disease in pediatric population is a rare disease but may cause a significant pain and disability. It has been estimated that 0.5-3% of all patients having lumbar disc surgery are below 18 years.<sup>10-12</sup> The unique physiological natures of children and adolescents endow pediatric lumbar disc disease with some distinctive features. Also due to different structural properties and environmental and occupational exposures, pediatric lumbar disc disease may be considered as a separate entity distinct from adult lumbar disc.<sup>6,10</sup> Reported outcome of lumbar disc surgery in pediatric population in the literatures is usually

favorable in comparison to reported outcome in adult population.<sup>11, 12, 14</sup> This emphasizes the distinct nature of this illness in pediatric population. This retrospective descriptive study concentrates on the peculiar characteristics of the lumbar disc disease in pediatrics population in terms of clinical, radiological, operative and outcome aspects.

## Patients & Methods

The medical records of all patients who had lumbar disc surgery in our hospital between 1996 and 2011 were reviewed. Only patients younger than 18 years were included in this study. We were able to trace 17 patients with complete follow-

up data and whom we were able to contact for the final follow-up evaluation. The preoperative clinical data were collected including family history and history of illness' precipitating event as well as general and neurological clinical assessment. The preoperative images and the detailed operative data were reviewed.

Finally the postoperative follow-up and the latest follow-up evaluation were documented. For the latest follow-up, evaluation of the patients was performed either through the outpatients' clinic or via telephone. Two schemes were used for the clinical evaluation. Firstly, pre- and post-operative back and leg pain was evaluated using the Visual Analogue Scale.<sup>23</sup> Patients were asked to allocate their back and leg pain along a scale that start from 0 and ends with 100 for both pre- and post-operative. Secondly, patients were categorized according to the following outcome grading system; excellent, good, fair, poor. Patients with excellent outcome have no limitation of their physical activities, where those with good outcome have minimal physical limitation. Patients with fair outcome have moderate physical limitation, and patients with poor outcome have severe physical limitation.

**Table1.** Summary of data of our 17 patients

No.	Age(yrs)/ Sex	Duration /Months	Trauma	Family History	Clinical Picture	Disc Level	Follow- up/mos	Clinical Outcome
1	16/M	8	LHW	+	LP, TH, N	5/1	24	1
2	17/M	12	LHW	+	LP,TH, BP	4/5	18	1
3	15/M	9	Fall	-	LP,TH, BP, N	4/5	12	2
4	14/F	3	Fall	+	LP,TH, BP, W	5/1	6	1
5	16/F	6	LHW	-	LP, N	3/4	24	1
6	14/M	24	No	-	LP, TH, BP	4/5, 5/1	20	3
7	14/M	24	LHW	+	LP,TH	4/5	12	2
8	17/F	12	No	+	LP, TH, BP, N	5/1	9	2
9	13/M	22	Fall	+	LP, N	4/5	72	1
10	12/M	18	No	-	LP, TH, BP	4/5, 5/1	30	2
11	15/M	10	Fall	-	LP, TH, BP, W, N	4/5	6	3
12	17/F	8	No	-	LP, TH, BP, W, N	4/5	10	1
13	16/M	15	LHW	+	LP, TH	4/5	20	2
14	15/M	6	LHW	+	LP, TH, BP, N	5/1	15	2
15	15/F	14	LHW	-	LP, BP, W	5/1	9	2
16	16M	20	LHW	-	LP, TH, BP, N	5/1	6	1
17	17/M	10	LHW	+	LP, TH, N	3/4	6	2

LP; leg pain, TH; tight hamstring, BP; back pain, W; weakness, N; numbness, LHW; lifting heavy weight, M; male, F; female

## Results

### Demographic Data

A total of 17 patients were enrolled in this study; 12 were males and 5 were females. The average age was 15.2±1.5 with a range that varied from 12 to 17 years. The average duration of symptoms prior to surgery was 13.1±6.6 that varied from 3 to 24 months. In 13 of a total of 17 of our patients an incidental event were incriminated as a cause of precipitating their illness. These events included heavy weight lifting in 9 patients and a fall accident in 4 patients. Only 4 of our patients had reported unknown cause of their illness. Nine of our patients had reported positive family history of surgically treated lumbar disc disease.

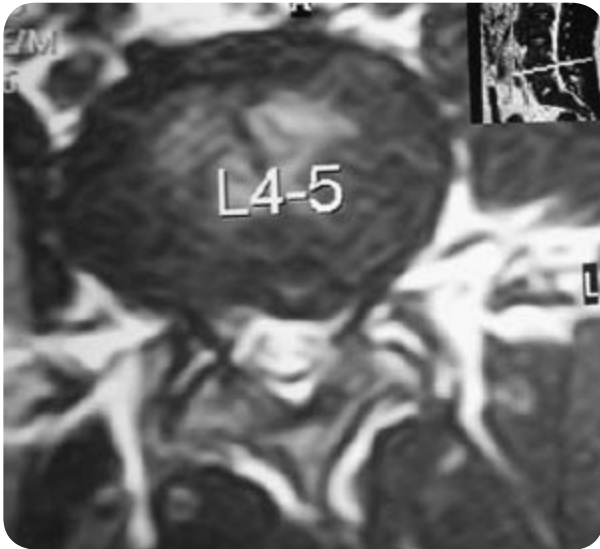
### Clinical Presentation

All patients in this study suffered from leg pain, where 11 patients suffered from back pain only, and 6 patients suffered from both back and leg pain. None of our patients operated for back pain only. 10 patients suffered leg numbness, where only 4 patients suffered from leg weakness in the affected root. Fourteen patients (82%) had positive straight leg raising test or tight hamstring. None of our patients suffered from sphincter problem. Data of our patients are detailed in table 1.

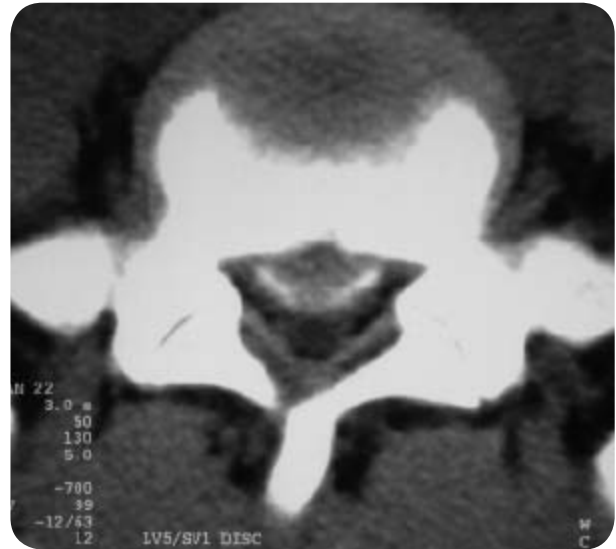## Radiographic Study

All patients were evaluated with plain radiography of the lumbosacral area. Five patients were evaluated with both MRI and CT scan, where 8 patients were evaluated with MRI only and 4 patients were evaluated with plain CT scan. Fifteen patients had single-level disc disease and 2 patients had double-level disc disease. Of the total 19 disc levels operated upon, L4/L5 disc was involved in 9 patients (47%), L5/S1 disc was involved in 8

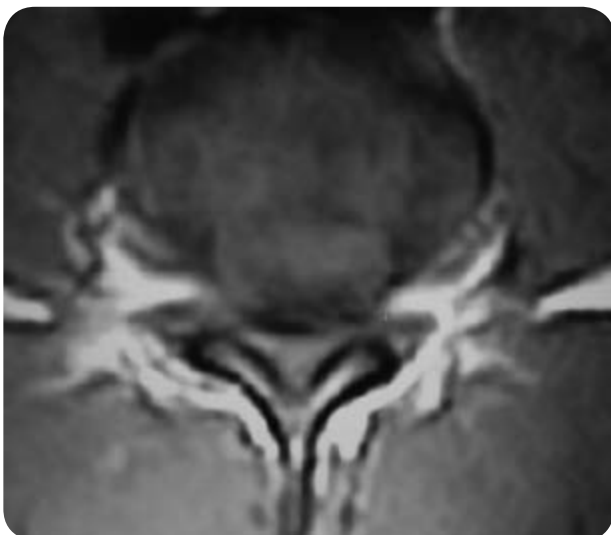
patients (42%), and L3/L4 disc was involved in 2 patients (11%). Only 5 (26%) disc levels were frank lateral disc prolapse (Figure 1), where the majority (74%, N=14) were either central or paramedian disc prolapse. Significant number of our patients (59%, N=10) suffered from vertebral endplate fracture (Figure 2, 3). Interestingly all operated lumbar discs in this study had bright white signal intensity on T2 weighted MR images (Figure 1, 3b). This reflects that these discs were not degenerated.



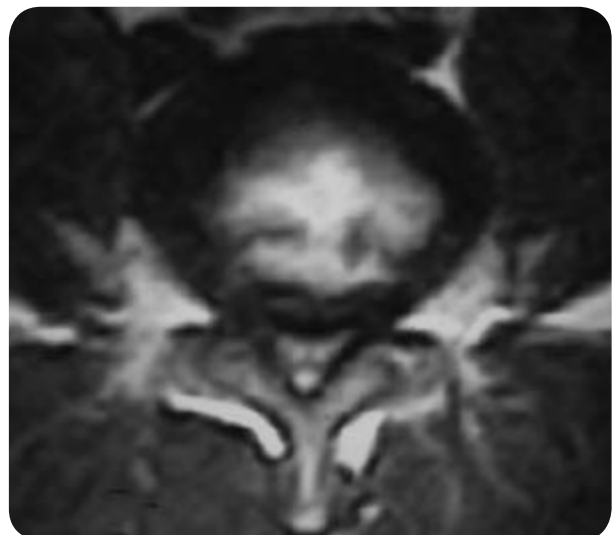
**Figure 1.** A T2 axial cut weighted MR image showing Left L4/5 disc prolapse impinging L5 root and narrowing the lateral recess. Of note also the bright signal intensity of the non-degenerated disc.



**Figure 2.** A CT scan image showing L5/S1 disc prolapse with avulsion of the epiphysis.



**Figure 3-a.** A T1 weighted axial cut MR image showing central L4/5 disc prolapse with avulsion of the epiphysis noted as a black edge around the disc.



**Figure 3-b.** a T2 weighted axial cut MR image showing a central L4/5 disc with avulsed epiphysis noted as a black edge around the disc. Note also the bright signal intensity of the disc denoting that the disc is not degenerated.

## Surgical Procedure

The surgical procedure was performed via the posterior midline approach while patients were in the prone position using Wilson laminectomy frame. Through a midline incision, subperiosteal dissection was performed to expose the interlaminar space. Seven patients had unilateral procedure, while the vast majority of patients (59%, N=10) had bilateral procedures to enable full resection of the fractured protruded endplate and decompress the roots bilaterally. With the aid of the surgical loop 2.5X, a small keyhole laminotomy was performed, as needed, using Kerrison rongeurs. The ligamentum flavum was removed and identification of the exiting nerve root was performed. Foraminotomy and disc excision were performed sequentially. In correlation with the bright white signal intensity observed on T2 weighted MR images, removal of disc proved that majority of discs were soft jelly-like substance. It took us a lot of time and frequent numbers of going in and out of the disc to remove it.

## Clinical Outcome

Reviewing the medical records of our patients has shown that during the early follow-up period (3 months), residual radicular pain was noticed in one patient, residual weakness in another patient, residual paresthesia in 2 patients, and tight hamstring persisted in 4 patients (24%). With time these manifestations has changed, and last follow-up has shown that back pain was reported in 2 patients (12%), root pain in one patient, paresthesia in 2 (12%), root weakness and tight hamstring in no patients. Over all 3 patients (18%) were used to have some irregular analgesia non of them had significant disability. There was no reported morbidity in this study. The average clinical follow-up of our patients in this study was  $12.1 \pm 13$  that varied from 6 to 72 months. According to the outcome scale used in this study, an excellent outcome (no physical limitation) was reported in 7 patients (41%), where 8 patients (47%) reported good outcome (minimal physical limitation). Fair outcome (moderate physical limitation) was reported in 2 of our patients (12%), and none of our patients had poor outcome (severe physical limitation). According to the Visual Analogue Scale used in this study, reported back pain has changed from average 78.5 pre-operatively to 32.2 post-operatively, whereas leg pain has changed from average 92.5 pre-operatively to 21.3 post-operatively.

## Discussion

The unique physiological natures of children and adolescents endow pediatric lumbar disc disease with some distinctive features. The structural properties and environmental and occupational exposures of pediatric patients are also different from adults.<sup>6, 10</sup> Still the issues of compensation, work conditions, psychiatric problems, drug abuse, and mechanical back pain, all these factors contribute to economic and functional disability in adult.<sup>7, 21</sup> Pediatric patients rarely experience any of these problems. The end result of these conditions may allocate the pediatric lumbar disc disease as a separate entity distinct from adult lumbar disc. We reviewed our data and many other reviewed series in the literature trying to test the hypothesis that pediatric disc disease and surgery are different from adult ones in many aspects.

## Demographic

Reviewing our study's demographic data showed it was more or less similar to other reports. In this study 71% of overall 17 patients were males. The high incidence of males reflects the exposure of males to the risk factor of the illness and early exposure to tough working condition as well as street or regular sport in our society. Overall 76% of our patients had reported different types of trauma as a precipitating cause of their illness. Reported incidence of trauma in previous series varies between 30-60%.<sup>2, 3, 6, 10, 11, 13, 19, 24</sup> The type of trauma varies according to the social and economic factors, while early working exposure in children is high in underdeveloped countries like ours, sports predominate in developed countries. This also affects the gender as a high incidence of males in underdeveloped countries like ours. Reported lumbar disc surgery in families of our patients or genetic predisposition was 51% where other reports<sup>6, 8, 10, 24, 25</sup> showed an incidence between 13 and 57%.

## Clinical

The clinical data in this study as supported with other reports<sup>2, 19</sup> were generally similar to adult with some distinctive features for the pediatric patients. All our patients suffered from leg pain, where others<sup>3, 10, 27</sup> reported an incidence of 100%, 95%, 90% respectively. Back pain was reported in 65% of our patients, where others<sup>3, 10</sup> reported an incidence of 85%, 65% respectively. Sensory affection was documented in 59% of ours, where others<sup>3, 10</sup> had reported an incidence of 52%, 41%,



respectively. Observed weakness in ours was 24% where others<sup>3, 10, 27</sup> had observed an incidence of 55%, 33%, 26% respectively. Finally, hamstring tightness was documented in 85% of ours where others<sup>3, 13</sup> had reported 95%, 90% respectively. The reported data mentioned above showed that pediatric patients tend to have a greater nerve root tension resulting in hamstring tightness than adults.<sup>17</sup> However, pediatric patients are less often seen with neurological symptoms such as weakness.<sup>5, 18</sup> Otherwise, clinical presentation was generally similar to that reported in adults.

### **Radiographic**

Some results reported here were generally similar to adult reports where other was peculiar for pediatric age. In our study 88% of patients had single-level disc prolapse. This was reported in most series, and a figure of 90%, 88% was reported respectively by others.<sup>3, 25</sup> The offending disc involved LV4/5 level in 47% and LV5/S1 level in 42% of our patients. This was generally similar to other series. LV4/5 level was reported by others<sup>11, 25</sup> in 66%, 47% of their patients respectively, and LV5/S1 level was reported by others<sup>11, 24, 25</sup> in 75%, 45, 34% of their patients respectively.

Slipped apophysis or fracture vertebral endplate was documented in 59% of our patients. Other authors<sup>1, 24, 25</sup> had reported an incidence of 40%, 32%, 15% respectively. Our high incidence of endplate slippage correlates well with the high incidence of trauma in this series. Plain radiographs revealed the fracture endplate in only 4 of the 10 patients, where Computed Tomographic (CT) findings were diagnostic in all patients examined with CT scan (Figure 1). Magnetic resonance (MR) images demonstrated the avulsed apophysis or endplate in all examined patients (Figure 2, a, b). Banerian (1) had reported the same results and showed that MRI can demonstrate the avulsed fragment with what are assumed to be the attached Sharpey's fibers on sagittal MR images, and added that these structures had a configuration with the appearance of a "Y" or "7" shape. Anatomically, the inter-vertebral discs are secured to their adjacent vertebral bodies by attachments of the outermost fibers of the annulus fibrosus (the Sharpey's fibers). In the developing spine, these Sharpey's fibers are embedded in the ring apophysis. Before fusion of the ring apophysis occurs at approximately 18 years of age, a relative weak point exists between the ring apophysis and the adjacent vertebral body. If inter-vertebral disc herniation occurs prior

to complete fusion of the ring apophysis to its adjacent vertebra, an associated avulsion fracture of the vertebral end plate may occur.<sup>1, 16, 26</sup>

### **Operative**

Operatively we were confronted with two types of patients. Patients with disc prolapsed, and patients with slipped end plates. Structurally, the pediatric disc has generally not undergone the same degenerative changes as in adults and it was quite rare in agreement with Cahill et al.<sup>3</sup>, to get a large free fragment of disc at surgery despite what appears to be significant compression on imaging. At surgery the disc handles as a very structurally tough tissue and comes out in multiple small fragments. It was not uncommon to pass the disc rongeur more and more times than usual to get adequate disc removal and root decompression. This reflects the non-degenerative nature of the prolapsed pediatric disc. Sometimes the patients appeared to have heavily calcified discs and required a chisel to break up the shell of the disc. This may reflect the younger child's increased ability to generate new bone quickly. An understanding of the physical toughness of the disc and patience during the surgery are important to successful outcomes.

The high incidence of the slipped end plate has a great impact on the surgical procedure. We agree with others<sup>1, 4</sup> that the preoperative recognition of this condition is mandatory because the removal of disc material alone may not be sufficient to relieve nerve root impingement. In patients in whom this condition went unrecognized or untreated, there is a possibility that this fracture could heal with residual stenosis. Another implication since the fracture fragment is less pliable than disc material, a wider bilateral exposure is often necessary for its removal. This was observed in 59% of our patients. This was also reported by others<sup>1</sup> who had reported an incidence of 67% of bilateral laminotomy.

### **Outcome**

It has been reported that lumbar disc surgery was generally associated with good clinical outcome.<sup>6, 10, 11, 12, 14, 24</sup> Excellent outcome was reported in 41% of our patients, where 47% reported a good outcome, summing up to a total of 88% success rate. This success rate was generally close to other reports<sup>11, 15, 18, 20, 24, 25</sup> who documented a success rate of 100%, 100%, 95%, 95%, 92%, 65% respectively. In this study 12% of our patients had some postoperative back pain that was adequately controlled with pain killers and was not significantly

affecting physical activities. This was comparable to other reported literature. Durham et al.,<sup>10</sup> in their study found that lumbar disc disease in the pediatric population does not appear to lead to chronic complaints of back pain, and it does not appear to have a negative impact on overall health. They postulated that this finding suggests that pediatric lumbar disc disease may be a separate entity distinct from adult lumbar disc disease. In their study they reported a score 18.4 post-operative back pain and when they compare their results to similar study<sup>22</sup> in adult they noticed a nearly double score of 36.3 of post-operative back pain.

During our 12.1 months follow-up period none of our patients had reoperation. This is due to the short period of follow-up. In a longer follow-up series, a figure of 20% reoperation rate during 10 years of follow-up was reported.<sup>9, 11</sup> Where, a figure of 24% reoperation rate was also reported in 8.5 years follow-up.<sup>10</sup> Another report<sup>25</sup> showed redo rate of 15% at 8.9 years. However Cahill et al.<sup>3</sup> reported a 6% reoperation rate during an average follow-up period of 12.2 months. This stresses the importance of long-term follow-up in order to test the validity of reported reoperation rate.

Through this study we came across many limitation in our as well as in many other reports in the literature. The limitation of this analysis relates to its retrospective design without conditioned-specific functional outcomes scales. It appears that obtaining formal functional outcome measures to determine postoperative quality of life and level of disability in a retrospective and prospective manner is mandatory.

## Conclusion

Lumbar disc surgery in pediatric patients is safe, efficacious, and does not lead to chronic back illness or affect physical activity of patients. Due to many distinguished features It should be considered as a special clinical entity distinct from adult disease.

## References

- Banerian KG, Wang AM, Samberg C, Kerr HH, Wesolowski AP. Association of Vertebral End Plate Fracture with Pediatric Lumbar Intervertebral Disk Herniation: Value of CT and MR Imaging. *Radiology* 1990, 177:763-765.
- Beks JW, ter Weeme CA. Herniated lumbar discs in teenagers. *Acta Neurochir (Wien)* 1975, 31:195-199.
- Cahill KS, Dunn I, Gunnarsson T, Proctor MR. Lumbar microdiscectomy in pediatric patients: a large single-institution series. *J Neurosurg Spine*, 2010, 12:165-170.
- Callahan D, Pack L, Bream R, Hensing R. Intervertebral disc impingement syndrome in a child. *Spine* 1986, 11:402-404.
- Clarke NM, Cleak DK. Intervertebral lumbar disc prolapsed in children and adolescents. *J Pediatr Orthop* 1983, 3:202-206.
- Dang L, Liu Z. A review of current treatment for lumbar disc herniation in children and adolescent. *Eur Spine J* 2010, 19:205-214.
- Davis RA. A long-term outcome analysis 984 surgically treated herniated lumbar discs. *J Neurosurg* 1994, 80:415-421.
- DeLuca PF, Mason DE, Weiland R, Howard R, Bassett GS. Excision of herniated nucleus pulposus in children and adolescents. *J Pediatr Orthop* 1994, 14:318-322.
- DeOrio JK, Bianco AJ Jr. Lumbar disc excision in children and adolescents. *J Bone Joint Surg Am* 1982, 64:991-996.
- Durham SR, Sun PP, Sutton LN. Surgically treated lumbar disc disease in the pediatric population: an outcome study; *Journal of Neurosurgery: Spine* 2000, 92(1): 1-6.
- Ebersold MJ, Quast LM, Bianco AJ Jr. Results of lumbar discectomy in the pediatric patient. *J Neurosurg* 1987, 67:643-647.
- Fisher RG, Saunders RL. Lumbar disc protrusion in children. *J Neurosurg* 1981; 54:480-483.
- Gennuso R, Humphreys RP, Hoffman HJ, Hendrick EB, Drake JM. Lumbar intervertebral disc disease in the pediatric population. *Pediatr Neurosurg* 1992, 18:282-286.
- Ishihara H, Matsui H, Hirano N, Tsuji H (1997) Lumbar intervertebral disc herniation in children less than 16 years of age. Long-term follow-up study of surgically managed cases. *Spine* 22:2044-2049.
- Kumar R, Kumar V, Das NK, Behari S, Mahapatra AK. Adolescent lumbar disc disease: findings and outcome. *Childs Nerv Syst* 2007, 23:1295-1299.
- Lowrey JJ. Dislocated lumbar vertebral epiphysis in adolescent children. *J Neurosurg* 1973; 38:232-234.
- Matsui H, Kitagawa H, Kawaguchi Y, Tsuji H. Physiological changes of nerve root during posterior lumbar discectomy. *Spine* 1995, 20:654-659.

18. Ozgen S, Konya D, Toktas OZ, Dagecinar A, Ozek MM. Lumbar disc herniation in adolescence. *Pediatr Neurosurg* 2007, 43:77–81.
19. Papagelopoulos PJ, Shaughnessy WJ, Ebersold MJ, Bianco AJ Jr, Quast LM. Long-term outcome of lumbar discectomy in children and adolescents sixteen years of age or younger. *J Bone Joint Surg Am* 1998, 80:689–698.
20. Parisini P, Di Silvestre M, Greggi T, Miglietta A, Paderni S. Lumbar disc excision in children and adolescents. *Spine* 2001, 26:1997–2000.
21. Quigley M, Bost J, Maroon J, et al. Outcome after microdiscectomy: results of a prospective single institutional study. *Surg Neurol* 1998, 49:263-268.
22. Ruta DA, Garratt AM, Wardlaw D, et al. Developing a valid and reliable measure of health outcome for patients with low back pain. *Spine* 1994, 19:1887-1896.
23. Scott J, Husksson EC. Graphic representation of pain. *Pain* 1976, 2:175-184.
24. Shillito J Jr. Pediatric lumbar disc surgery: 20 patients under 15 years of age. *Surg Neurol*. 1996 Jul;46(1):14-8.
25. Smorgick Y, Floman Y, Millgram MA, Anekstein Y, Pekarsky I, Mirovsky Y. Mid- to long-term outcome of disc excision in adolescent disc herniation. *Spine J*. 2006;6(4):380-4.
26. Takata K, Inoue S, Takahashi K, Ohtsuka Y. Fracture of the posterior margin of a lumbar vertebral body. *J Bone Joint Surg (Am)* 1988; 70:589-594.
27. Thomas JG, Hwang SW, Whitehead WE, Curry DJ, Luerssen TJ, Jea A. Minimally invasive lumbar microdiscectomy in pediatric patients: a series of 6 patients. *J Neurosurg Ped*, 2011, 7(6): 616-619.

Address reprint  
request to:

**Ali Abou-Madawi, MD**

Neurosurgical department, Suez Canal University, Ismailia, Egypt.  
Email: aamadawi@yahoo.com

## الملخص العربي

**جراحة الغضروف القطني في الأطفال: هل هي كينونة خاصة غير الكبار؟**  
الخلفية: تندر إصابة الأطفال بالانزلاق الغضروفي القطني إلا أن ذلك قد يؤدي إلى آلام وإعاقة مهمة. نظرا لاختلاف الخصائص التركيبية، التعرضات البيئية والعملية المختلفة قد يؤدي ذلك لتصنيفها كحالة مختلفة عن الكبار.  
الهدف: تهدف هذه الدراسة التحليلية إلى تحديد النتائج السريرية والخصائص المميزة للانزلاق الغضروفي القطني في الأطفال.  
الطريقة: تمت مراجعة ملفات المرض أصحاب الأعمار ١٨ عاما أو أقل الذين أجريت لهم جراحة استئصال الغضروف القطني بين عامي ١٩٩٦ و ٢٠١١. تمت مراجعة بياناتهم الخاصة بالفحوصات السريرية والأشعة وتقارير العمليات والبيانات السريرية لما بعد الجراحة.  
النتائج: تم إدراج ١٧ مريضا ١٢ ذكور و ٥ اناث. بلغ متوسط العمر ١٥ عاما. كذلك بلغت متوسط فترة المرض قبل الجراحة ٩:٦ شهرا. كان متوسط فترة المتابعة ١٢ شهرا. عانى كل المرضى من عرق الانس. ٢٤% من الضعف العضلي. ٥٩% من الخذل و ٨٢% من اختبار الساق المستقيمة. كانت النتائج ممتازة في ٤١%، جيدة في ٤٧% و متوسطة في ٢١% من المرضى. انخفض معدل المضاهاة البصرى لألم الظهر من ٧٨ الى ٣٢ و كذلك لألم الساق من ٩٢ الى ٢١.  
الاستنتاجات: تعتبر جراحة الغضروف القطني في الأطفال آمنة ولا تؤدي إلى آلام مزمنة بالظهر ولا تؤثر على النشاط الطبيعي للمرضى. يجب اعتبار هذه الحالة كينونة مختلفة في خاصة للصغار عن الكبار.