

Partial pedicle subtraction osteotomy (PPSO): A modification for PSO in treatment of sagittal deformities.

Mohamed wafa; MD, Ahmed El-Badrawi; MD, Fady Michael; MD.

Orthopedic department, EinShams University, Cairo, Egypt.

Abstract

Background data: Pedicle subtraction osteotomy is used for treatment of sagittal deformities. It has the advantages of being accomplished completely through a posterior approach. Neurological deficits that accompany the procedure are believed to be the result of a combination of subluxation, residual dorsal impingement, and dural buckling.

Purpose: To introduce a new modification of the traditional pedicle subtraction osteotomy, in which we perform partial pedicle osteotomy; preserving the inferior third of the pedicle. This allows more smooth correction of the deformity, minimizes the injury or irritation of the nerve root below this pedicle, and decreases the incidence of subluxation and dorsal impingement. Since the correction occurs with theoretically smaller wedges, better closure and union of the osteotomy site is expected.

Study design: Our retrospective study included 33 patients with sagittal plan deformity (16 cases of ankylosing spondylitis, 8 cases of old fractures, 5 cases of congenital kyphosis and 4 cases of postlaminectomy kyphosis after cord tumour resection).

Methods: All patients were treated by our modifications of the pedicle subtraction osteotomy technique. Radiographic analysis included assessment of kyphosis by regional Cobb angle, and the CV7 sagittal plumb line in pre and post plain radiographs. Clinically, the patients are assessed by the Oswestry functional score.

Results: Our series included 23 male and 10 females. The age was of a mean 42.3 years. The vertical plumb line distance from the first sacral segment improved to 3.4 cm compared to a mean of 9.3 preoperatively. The degree of correction for single osteotomy was of a mean of 22.4°. The intervertebral foramen below the osteotomised pedicle showed unchanged vertical dimension after the osteotomy. The complications included 4 cases of dural tears, 1 case of massive bleeding (2500 ml), 3 cases of superficial wound infection, and 1 case developed transient postoperative paraparesis. There was no single case of root injury. The follow-up of the patients was of mean 27.4 months. At the end of follow up, radiologically, there was a loss of correction of mean of 2 degrees with no case of pseudoarthrosis or metal failure. According to Oswestry disability score, 88% of patients were able to return to their normal to moderate daily activities with good self image and overall satisfaction.

Conclusion: Although our new technique is technically demanding, it has lower rate of neurological complication with better chances of union than the traditional osteotomy.

(2012ESJ007)

Key words: Pedicle Subtraction Osteotomy, PSO, Kyphosis, Sagittal, Deformity.

Introduction

The spine curves with their alternating concavities between lordosis and kyphosis should result in a balanced head over the sacrum to maximize the efficiency of ambulation and posture with the least muscle energy expenditure. The disturbance of the magnitude of these curves will result in sagittal imbalance, excessive energy expenditure which will result in muscle fatigue and pain. Also, sagittal imbalance may disturb the forward gaze beside being cosmetically unacceptable by the patients³.

Spine imbalance due to sagittal deformities leads to compensatory postures that place the body at a biomechanical disadvantage and an inefficient use of muscle energy resulting in strain, fatigue, and pain. Traditionally this deformity has been treated with extension osteotomies at the level of the deformity.⁶ Pedicle subtraction osteotomy has the advantages of being accomplished completely through a posterior approach without the need for an anterior procedure. Neurological deficits that accompany the procedure are believed to be the result of a combination of subluxation, residual dorsal impingement, and dural buckling⁸.

Pedicle subtraction osteotomy had been proposed and widely used surgical technique for treatment of sagittal imbalance due to kyphotic situations. But this technique does not go without complications. We introduce a new modification of this widely accepted technique that we believe that it may decrease its complications especially the neurological deficits.

Patients and methods

This is a retrospective study that included 33 patients who have been operated between 2004 and 2007. The patients were as follow; 16 cases of ankylosing spondylitis, 8 cases of old fractures, 5 cases of congenital kyphosis and 4 cases of postlaminectomy kyphosis after cord tumour resection. 9 patients in our series were presented by neurological deficits. Preoperatively the patients were evaluated by both plain radiography and MRI. The plain x-rays used to quantify the degree of kyphosis using the regional Cobb angle and the distance from the posterior superior endplate of SV1 vertebral body and the vertical plumb line. The anteroposterior view serves to detect any associated coronal deformity.

Our technique of partial pedicle subtraction osteotomy consists of the same steps as the

traditional PSO to expose the desired pedicle for osteotomy after fixation of the planed levels without assembling the construct; pedicle screws in all cases; to the rods. Once the pedicle is exposed after de-roofing of both the intervertebral foramen above and below it, our osteotomy is done preserving the inferior third of the pedicle. We perform our first line of the wedge osteotomy using a sharp osteotome above the superior wall of the pedicle; through the vertebral body till the anterior cortex. The second line of osteotomy is done by introducing the osteotome through the pedicle preserving its inferior one third which protects the underling nerve root. (Figure 1) The nerve root is mildly retracted to protect it as it passes medial to the pedicle. The inferior line of osteotomy is inclined to meet the first line just posterior to the anterior cortex of the vertebral body preserving this cortex to act as a hinge during closure of this wedge. The two osteotomes remain in place and the position is verified by a lateral view using the image intensifier. Once the position of both osteotomes is accepted, the same maneuver is repeated in the contra lateral pedicle of the same vertebra. The resulted bony wedge is removed including its posterior cortex using curved curettes to prevent posterior buckling against the dura. Once we are sure that the whole circumference of the dura is free and the posterior cortex of the wedge is totally removed, we extend the operating table and our construct is assembled to the rod with compression at the site of osteotomy to close our wedge hinging over the intact anterior cortex of the vertebral body. As a final step, we recheck the anterior dural surface and the roots exiting near by the osteotomy to assure their freedom and absence of any compression

In cases of global loss of the lumbar lordosis; the 16 cases of ankylosing spondylitis; we prefer to perform a double level osteotomy (usually at LV2 and LV4) with the same technique to produce more smooth correction of the lumbar curve. In these cases of ankylosing spondylitis, thoracic hyper kyphosis was a component of the deformity. We prefer to perform posterior V shaped osteotomy at the dorsal spine to achieve additive dorsal correction. This is accomplished by removal of the adjacent parts of 2 successive laminae, spinous processes, ligamentum flavum and facet joints (figure 2). The number and levels of this osteotomy are individualized to every case on the preoperative scanogram plane depending on the degree of the

deformity, the degree of correction of the vertical plumb line distance after the lumbar osteotomies and the whole sagittal balance required.

All patients were evaluated by Oswestry functional score for clinical assessment and follow up. The postoperative radiographs were evaluated for the correction of the regional Cobb angle and

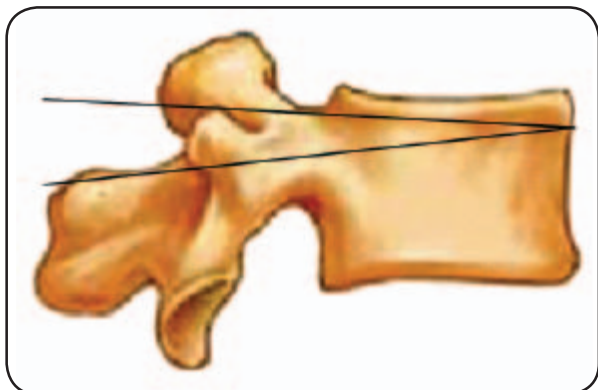


Figure 1. Lateral view of lumbar vertebra with the lines of partial pedicle subtraction osteotomy. Notice that the inferior line is through the pedicle leaving the inferior third of the pedicle intact to protect the underlying exiting nerve root.

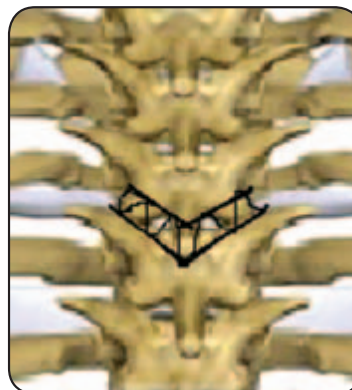

Figure 2. The V shaped osteotomy of the dorsal spine. The shaded area is removed from the posterior elements to allow closure of the osteotomy achieved by posterior compression of adjacent pedicle screws.

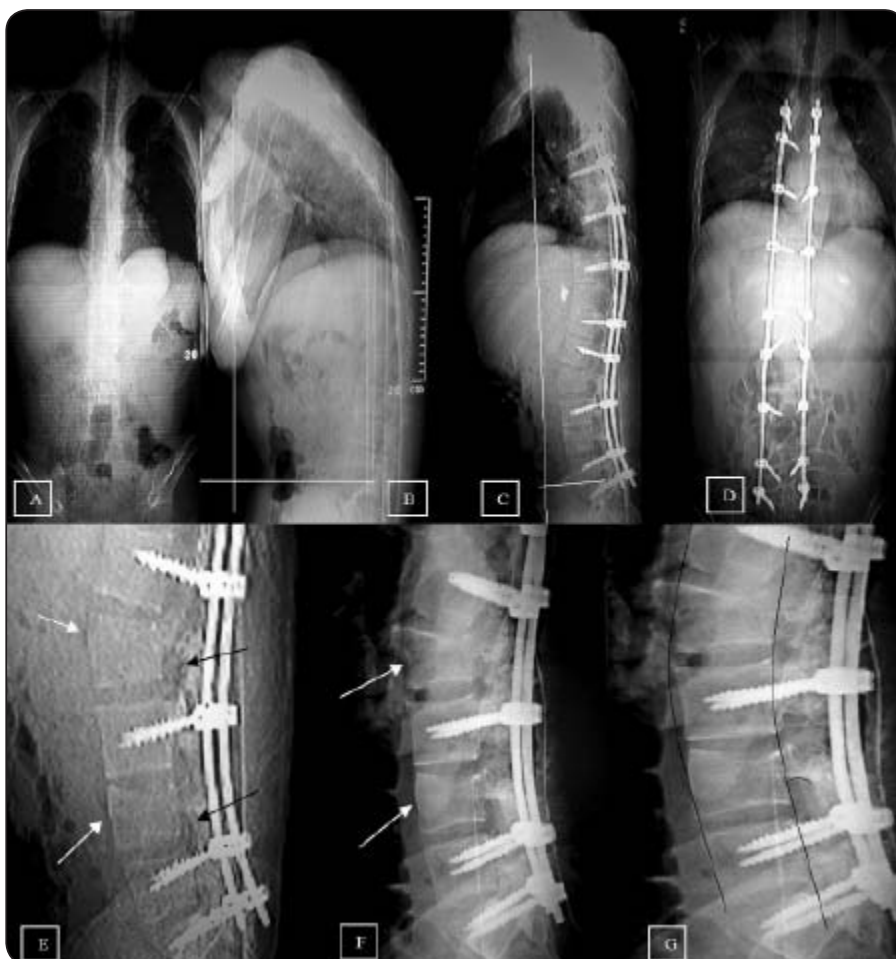

Figure 3. Male patient, 38 years old, ankylosing spondylitis with sagittal imbalance. (A), (B) Preoperative long film spine scanogram with the vertical plumb line in white color. (C), (D) Postoperative spine scanogram with improvement of vertical plumb line distance (E), (F), (G) Postoperative Lumbar spine showing osteotomy at LV2, LV4 with smooth correction of lumbar spine with no evidence of subluxation at the level of osteotomy (black lines in (G)). The inferior smooth pedicle wall is preserved with unchanged vertical dimension of the intervertebral foramen (black arrows) and complete closure of the wedge osteotomy (white arrows).

Results

Our series included 23 male and 10 females. The age group varies from 5 years old to 65 years with a mean of 42.3 years. The mean intra operative bleeding was 1350 ml and operative time was 235 minutes. The vertical plumb line distance from the first sacral segment was of mean 9.3cm. The average regional Cobb angle ranged from 7° to 115° with a mean 49.8°. The postoperative Plumb line improved to 3.4cm and there was a mean correction of 45.3° for the regional Cobb angle. In our series, the degree of correction in cases of single osteotomy varies between 19° to 31° with a mean 22.4°. The intervertebral foramen below the osteotomised pedicle showed unchanged vertical dimension after the osteotomy owing to the preservation of the inferior wall of the pedicle while the foramen above the pedicle is enlarged distally.

The intra operative complications included 4 cases of dural tears that were managed by direct repair and 1 case of massive bleeding (2500 ml). There was no single case of root injury. The postoperative complications included 3 cases of superficial wound infection that needed

debridement and 4 cases of prolonged serous discharge for more than 5 days. The infection was subsided and the patients remained under antibiotic cover for at least three weeks. Only 1 case developed postoperative paraparesis that was recovered completely within three months. 6 patients with preoperative neurologic deficits were improved at least one grade on Frankle grading system. One case of postlaminectomy kyphosis after cord tumour resection developed unexplained neurologic deterioration six weeks postoperative that was attributed by neurosurgeons to the preexisting cord pathology. One case was complicated with postoperative cerebrovascular stroke due to diabetes and atherosclerosis.

The follow-up of the patients was of mean 27.4 months. The minimum follow-up is 25 months at time of editing this paper in June 2011. The maximum was 66 months. At the end of follow up, radiologically, there is a loss of correction of mean of 2 degrees with no case of pseudoarthrosis or metal failure. According to Oswestry functional score, 88% of patients were able to return to their normal / average daily activities with good self image and overall satisfaction.

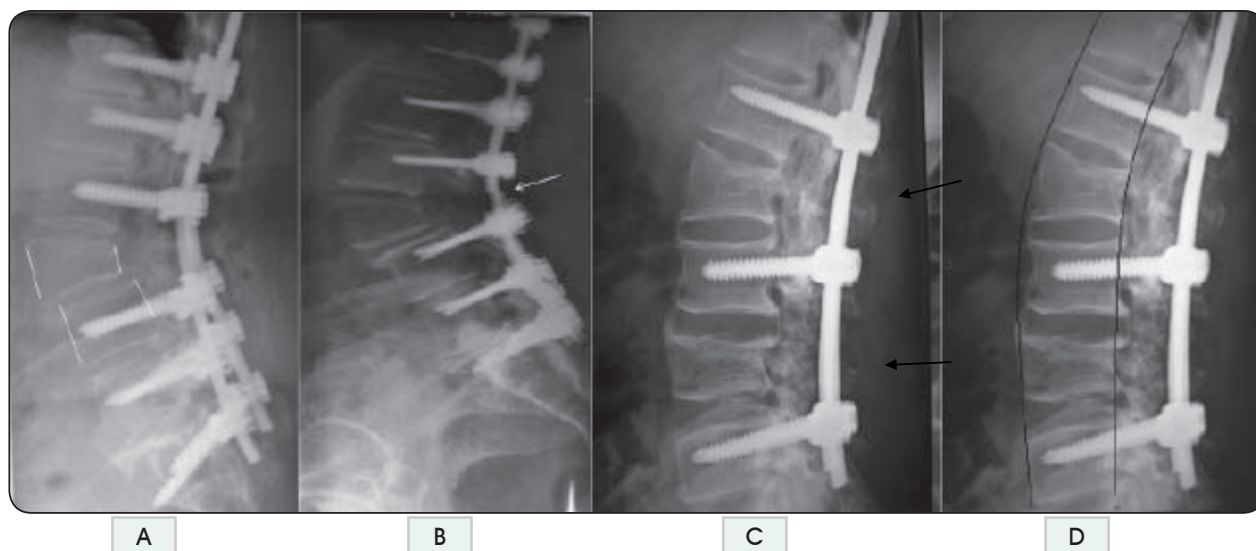


Figure 4. (A): A case of traditional pedicle subtraction osteotomy complicated with subluxation (spondylolysis) of LV3 (white lines). (B): Another case complicated with both subluxation metal failure (white arrow). This may be attributed to large degree of correction through only one osteotomy at LV3. Also LV3 is connected to the spinal column only by the intervertebral disc and anterior longitudinal ligament with much stresses implied on the metal implants till the intertransverse fusion occurs. (C), (D): A case of partial pedicle subtraction osteotomy done at LV2, LV4 at the end of follow up shows no evidence of any subluxation, smooth correction of lumbar lordosis (black lines), intervertebral foramen maintained and union of the osteotomy sites. Near normal anatomy of LV2, LV4 due to union of the remained lower 1/3 of the pedicle with the posterior fusion mass (black arrows).

Discussion

The development of osteotomy techniques has advanced spine surgeons' ability to treat spinal deformities.⁹ The shift away from simple compression/distraction or cantilever maneuvers as a mean of realigning the spine in favor of vertebral column osteotomies and resections with posterior column shortening has been an important philosophical and practical paradigm shift away from combined anterior-posterior procedures.^{2,10}

A unifying feature of Smith Peterson osteotomy is shortening of the posterior column accompanied by elongation of the anterior column. Although there are many reports of successful Smith-Petersen osteotomies,^{3,4,13,14} lengthening of the anterior column has been associated with disastrous complications, such as fatal aortic rupture, superior mesenteric artery syndrome, cauda equina syndrome, paraplegia, and paralytic ileus.^{1,12,15,16}

Pedicle subtraction osteotomy is relatively aggressive resection of a wedge of bone, including posterior elements, the pedicles and the vertebral body.⁷ There are several advantages of pedicle subtraction closing wedge osteotomy. Correction is obtained through all three columns of the spine. This allows for correction in both the sagittal and coronal plane. In addition, the spine is not lengthened, thereby avoiding the vascular and abdominal complications associated with extension osteotomies. The bone surface for fusion is large and placed under compression by the mechanics of the osteotomy. The instrumentation is therefore used to maintain the alignment as opposed to creating the desired alignment. Cho et al demonstrated that the corrections per segment were 10.7 for Smith Peterson osteotomy and 31.7 for pedicle subtraction osteotomy.⁶

Many authors demonstrated good and satisfactory results with this technique in treatment of sagittal plane deformities.^{5,11,15} Closing-wedge osteotomy appears to provide satisfactory sagittal plane correction with superior results and a relatively low rate of serious complications in comparison to opening-wedge osteotomy and polysegmental wedge osteotomy in patients with ankylosing spondylitis.¹⁵

But, pedicle subtraction osteotomy is technically demanding and neurological complications may occur. Jacob M. Buchowski and associates reviewed all 110 patients treated with a PSO at

their institution over a recent 10-year period and found that intra- and postoperative deficits were seen in 12 (10.9%) patients and permanent deficits in 3 (2.8%) patients. Deficits were believed to be the result of a combination of subluxation, residual dorsal impingement, and dural buckling.⁸ Van Royen BJ listed among the complications of his series postoperative nerve root compression requiring reoperation.¹⁵

As we believe that pedicle subtraction osteotomy provides very satisfactory results for treatment of sagittal imbalance, we developed our modification as a trial to decrease its complications. Since the exiting nerve root occupies the upper third of the intervertebral foramen, in our modification we preserve the inferior wall of the pedicle with its smooth cortex to protect the exiting nerve root during cutting through the pedicle and closure of the osteotomy. The vertical diameter of the foramen was not changed postoperatively that resulted in absence of any root compression or injury.

Our technique of partial pedicle subtraction osteotomy provides smaller wedge which we believe to be advantageous. The closure of this wedge is easier with no need for excessive compressive forces which stresses the fixation and endangers its stability on both the short and long terms. Also, this smaller wedge allows better apposition and compression of the osteotomy surfaces and therefore better healing with lower chances for pseudoarthrosis at the osteotomy site. Being a smaller wedge, it decreases the incidence of anterior subluxation that resulted due closing of large wedges which endangers the neural elements posteriorly due to kinking at the osteotomy sites. This is very beneficial in high degrees of deformity or cases where the deformity is global to the whole region as in ankylosing spondylitis. For this we prefer to perform double level osteotomy; above and below the apex of deformity; with our technique rather than a single large osteotomy at the apex. This provides more smooth correction of the deformity; rather than the sharp correction at one level, with better chances to close the wedges properly and low incidence of subluxations. Although double osteotomies increases the surface needed to fuse, the small wedges are usually compressed perfectly which highly decreases the incidence of non union. Lastly, the remained part of the pedicle may give the surgeon a landmark after disturbance of the anatomy in this region

in cases of revision surgeries and fortunately it may adhere to the posterior fusion mass when fusion accomplished to connect the osteotomized vertebra to the posterior element again.

We admit that this operation doesn't go without complications. But all the complications we confronted related to any extensive spine operation (multilevel pedicle fixation, extensive decompression, posterior handling of anterior structures) and not to the technique described. Also most of these complications were in the early cases when the idea and technique was still developing. Multiple level osteotomies may be more time consuming than single osteotomy. But we believe that the advantages we get can justify this disadvantage.

Conclusion

Our technique, partial pedicle subtraction osteotomy, is a modification to the traditional PSO which already has proved to give very satisfactory results in treatment of sagittal plan deformities. We aimed at decreasing the incidence of complications that may result from this technically demanding procedure. Our data gave an optimistic guide in the way of making this technique safer.

References

- 1) Adams CJ. Techniques, dangers and safeguards in osteotomy of the spine. *J Bone Joint Surg (Br)* 34:226–231, 1952.
- 2) Bohm H, Harms J, Donk R, et al. Correction and stabilization of angular kyphosis. *Clin Orthop* 258:56–61, 1990.
- 3) Bradford DS, Schumacher WL, Lonstein JE, et al. Ankylosing spondylitis: experience in surgical management of 21 patients. *Spine* 12:238–243, 1987.
- 4) Camargo FP, Cordeiro EN, Napoli MM. Corrective osteotomy of the spine in ankylosing spondylitis. Experience with 66 cases. *Clin Orthop* 208: 157–167, 1986.
- 5) Chen IH, Chien JT, Yu TC. Transpedicular wedge osteotomy for correction of thoracolumbar kyphosis in ankylosing spondylitis: experience with 78 patients. *Spine* 26:E354–E360, 2001.
- 6) Cho KJ, Bridwell KH, Lenke LG, et al. Comparison of Smith Peterson versus pedicle subtraction osteotomy for the correction of fixed sagittal imbalance. *Spine*. 30(18):2030-7, 2005
- 7) Hehne HJ, Zeilke K, Bohm H. Polysegmental lumbar osteotomies and transpedicled fixation for correction of long curved kyphotic deformities in ankylosing spondylitis. Report on 177 cases. *Clin Orthop Relat Res* 258:49-55, 1990.
- 8) Jacob M. Buchowski. Presentation title: Neurologic Complications of a Pedicle Subtraction Osteotomy: a Ten-Year Assessment. Abstract P355, data presented at the 2007 Annual Meeting of the American Academy of Orthopedic Surgeons (AAOS).
- 9) Law WA. Osteotomy of the spine. *Clin Orthop* 6:70, 1969.
- 10) Leatherman KD, Dickson RA. Two-stage corrective surgery for congenital deformities of the spine. *J Bone Joint Surg (Br)* 61:324–8, 1979
- 11) Lazennec JY, Saillant G, Saidi K, et al. Surgery of the deformities in ankylosing spondylitis: our experience of lumbar osteotomies in 31 patients. *Eur Spine J* 6:222–232, 1997.
- 12) McMaster MJ, Coventry MB. Spinal osteotomy in ankylosing spondylitis. Technique, complications, and long-term results. *Mayo Clin Proc* 48:476–486, 1973.
- 13) Simmons EH. Kyphotic deformity of the spine in ankylosing spondylitis. *Clin Orthop* 128: 65–77, 1977.
- 14) Smith-Petersen MN, Larson CB, Aufranc OE. Osteotomy of the spine for correction for flexion deformity in rheumatoid arthritis. *J Bone Joint Surg (Br)* 27:1, 1945.
- 15) Van Royen BJ, De Gast A. Lumbar osteotomy for correction of thoracolumbar kyphotic deformity in ankylosing spondylitis. A structured review of three methods of treatment. *Ann Rheum Dis* 58:399–406, 1999.
- 16) Weatherley C, Jaffray D, Terry A. Vascular complications associated with osteotomy in ankylosing spondylitis: a report of two cases. *Spine* 13:43–46, 1988.

Address reprint
request to:

Mohamed wafa; MD,
Orthopedic department, EinShams University, Cairo, Egypt.
Email: mwafaspine@hotmail.com

الملخص العربي

المقدمة: أن تشوهات العمود الفقري التي تؤدي إلى فقدان الانحناءات الطبيعية للعمود الفقري تعالج بالقطع العظمي الكامل بساق الفقرة مما قد يؤدي إلى مضاعفات و اصابات عصبية إلى جانب ازدياد التحميل على الأعمدة المستخدمة. القطع الجزئي بساق الفقرة هو أسلوب جراحي جديد ابتكرناه للتغلب على هذه المضاعفات بما لا يؤثر على نتائج إصلاح هذه التشوهات. وشملت الدراسة ٣٣ مريضاً لدينا بأثر رجعي مع التشوه خطه السهمي (١٦ حالة من حالات تيبس العمود الفقري، و ٨ حالات الكسور القديمة، و ٥ حالات حداب الخلقي و ٤ حالات حداب بعد استئصال ورم بالحبل الشوكي).

الهدف: هو تقييم نتائج هذه الطريقة في علاج انحناء العمود الفقري.

الطرق: تم علاج جميع المرضى من خلال تعديلات لدينا من تقنية القطع الجزئي بساق الفقرة وتم الفحص الإكلينيكي وكذلك فحص بالإشاعات للحالات.

النتائج: وشملت سلسلة لدينا ٢٣ من الذكور والإناث ١٠. وكان في الفئة العمرية من ٤٢.٣ سنة. تحسين المسافة الرأسية من خط راسيا من العجزية الأولى إلى ٣.٤ سم بالمقارنة مع متوسط ٩.٣ قبل الجراحة. كانت درجة تصحيح المستوى الواحد متوسط ٢٢.٤ درجة. و المضاعفات شملت ٤ حالات من القطع السحائي، ١ حالة نزيف حاد (٢٥٠٠ مل)، و ٣ حالات الإصابة بتلوث سطحي، حالة واحدة عانت من ضعف مؤقت بعد الجراحة. لم يكن هناك حالة واحدة من الإصابة الجذرية للعصب. تم متابعة المرضى من أشهر ٢٧.٤، وهناك فقدان تصحيح من ٢ درجة مئوية، و ٨٨٪ من المرضى كانوا قادرين على العودة إلى وضعها الطبيعي إلى معدل الأنشطة اليومية مع صورة الذات الجيدة والرضا العام.

الاستنتاج: بالرغم من صعوبة هذه الطريقة فنحن نعتقد أنها مصحوبة بمعدل أقل من المضاعفات.